

# A Differential Clinical Benefit Examination of Full Lumbar Endoscopy vs Interspinous Process Spacers in the Treatment of Spinal Stenosis: An Effect Size Meta-Analysis of Clinical Outcomes

KAI-UWE LEWANDROWSKI<sup>1,2,3</sup>; IVO ABRAHAM, PHD<sup>4</sup>; JORGE FELIPE RAMÍREZ LEÓN, MD<sup>5,6</sup>;  
ROBERTO CANTÚ-LEAL, MD<sup>5,7,8</sup>; ROBERTO CANTÚ LONGORIA, MD<sup>8</sup>; JOSÉ ANTONIO SORIANO SÁNCHEZ<sup>9,10,11</sup>;  
AND ANTHONY YEUNG<sup>12,13</sup>

<sup>1</sup>Center for Advanced Spine Care of Southern Arizona and Surgical Institute of Tucson, Tucson, AZ, USA; <sup>2</sup>Department Neurosurgery, UNIRIO, Rio de Janeiro, Brazil; <sup>3</sup>Orthopaedic Surgery, Fundación Universitaria Sanitas, Clínica Reina Sofía – Clínica Colsanitas, Bogotá, DC, USA; <sup>4</sup>Pharmacy Practice and Science, Family and Community Medicine, Clinical Translational Sciences, University of Arizona, Tucson, AZ, USA; <sup>5</sup>Centro de Columna – Cirugía Mínima Invasiva, Bogotá, DC, USA; <sup>6</sup>Fundación Universitaria Sanitas, Bogotá, DC, USA; <sup>7</sup>Clínica Reina Sofía – Clínica Colsanitas, Bogotá, DC, USA; <sup>8</sup>Department of Spine Surgery, Hospital Christus Muguerza Alta Especialidad in Monterrey, Monterrey, Mexico; <sup>9</sup>Asociación Mexicana de Cirujanos de Columna, AMCICO, Ciudad de Mexico, Mexico; <sup>10</sup>Sociedad Mexicana de Cirugía Neurológica, SMCN, Ciudad de Mexico, Mexico; <sup>11</sup>Centro Médico ABC Campus Santa Fe, Ciudad de Mexico, Mexico; <sup>12</sup>Department of Neurosurgery Albuquerque, University of New Mexico School of Medicine, USA, Albuquerque, NM; <sup>13</sup>Desert Institute for Spine Care, Phoenix, AZ, USA

## ABSTRACT

**Study Design:** A design-agnostic standardized effect meta-analysis of 48 randomized, prospective, and retrospective studies on clinical outcomes with spinal endoscopic and interspinous process spacer (IPS) surgery.

**Objective:** The study aimed to provide reference set of Oswestry Disability Index (ODI) and visual analog scale (VAS) effect size data for back and leg pain following endoscopic and IPS decompression for lumbar herniated disc, foraminal, or lateral recess spinal stenosis.

**Background:** Mechanical low back pain following endoscopic transforaminal decompression may be more reliably reduced by simultaneous posterior column stabilization with IPS.

**Methods:** A systematic search of the PubMed, EMBASE, Web of Science, and the Cochrane Central Register of Controlled Trials from 1 January 2000 to 2 April 2020, identified 880 eligible endoscopy and 362 IPS studies varying in design and metrics. The authors compared calculated standardized effect sizes (Cohen's *d*) for extracted ODI, VAS-BACK, and VAS-LEG data.

**Results:** The pooled standardized effect size combining the ODI, VAS-BACK, and VAS-LEG data for the total sample of 19862 data sets from the 30 endoscopy and 18 IPS was 0.877 (95% CI = 0.857–0.898). When stratified by surgery, the combined effect sizes were 0.877 (95% CI = 0.849–0.905) for endoscopic decompression and 0.863 (95% CI = 0.796–0.930; *P* = 0.056) for IPS implantation. The ODI effect sizes calculated on 6462 samples with directly visualized endoscopic decompression were 0.917 (95% CI = 0.891–0.943) versus 0.798 (95% CI = 0.713–0.883; *P* < 0.001) with indirect IPS decompression (*P* < 0.001). The VAS-BACK effect sizes calculated on 3672 samples were 0.661 (95% CI = 0.585–0.738) for endoscopy and 0.784 (95% CI: 0.644–0.923; *P* = 0.187) for IPS. The VAS-LEG effect sizes calculated on 7890 samples were 0.885 (95% CI = 0.852–0.917) for endoscopic decompression and 0.851 (95% CI = 0.767–0.935; *P* = 0.427).

**Conclusion:** Lumbar IPS implantation produces larger reduction in low back pain than spinal endoscopy. On the basis of this meta-analysis, the combination of lumbar transforaminal endoscopy with simultaneous IPS has merits and should be formally investigated in higher grade clinical studies.

**Level of Evidence:** 2.

Endoscopic Minimally Invasive Surgery

Keywords: lumbar endoscopy, interspinous process spacer, herniated disc, spinal stenosis, meta-analysis

## INTRODUCTION

Considering stabilization after endoscopic decompression of a severely degenerated lumbar spinal motion segment has been suggested to improve clinical outcomes with this still relatively new outpatient spine surgery.<sup>1–3</sup> Spinal endoscopy is now increasingly

performed for claudication symptoms in the elderly due to herniated disc and spinal stenosis.<sup>2,4–10</sup> Degenerative disc disease is often associated with progressive loss of intervertebral height from vertical collapse, initially causing predominantly foraminal and lateral recess stenosis.<sup>11–15</sup> In its end stage, degenerative disc disease is known to result in loss of its internal structural

integrity, which is often corroborated by the presence of a vacuum phenomenon on radiographic studies.<sup>15,16</sup> The structural equivalents of such radiographic vacuum discs were recently described as intradiscal fissuring, cavitation, and delamination from the end plate often found during routine inside-out endoscopic direct visualization of the lumbar disc space in over two-thirds of affected patients.<sup>17</sup> Over time, additional instability-related problems may ensue due to altered facet joint biomechanics, eventually leading to its hypertrophy and hypertrophy of the ligamentum flavum compounding the stenosis problem.<sup>3,18,19</sup> Overgrowth of the ligamentum flavum has been stipulated to be a direct result of anterolateral instability,<sup>20</sup> thereby contributing to the late development of central stenosis in addition to foraminal or lateral recess stenosis often seen in the early stages of the disease.

Technological advancements in video endoscopic equipment and instruments afford the contemporary endoscopic spine surgeon the ability to tackle more complex problems, including those seen in patients with severe spinal stenosis. In experienced hands, good long-term outcomes can be achieved with both the inside-out<sup>21</sup> and the outside-in<sup>1</sup> transforaminal endoscopic decompression. Complication rates,<sup>22</sup> readmission rates,<sup>23</sup> reoperation rates, and conversion rates to open fusion surgery are substantially lower with the transforaminal endoscopic decompression surgery—particularly when expertly executed.<sup>24</sup> While the overall 5-year durability of the transforaminal endoscopic decompression was demonstrated to be excellent without the need for open salvage decompression fusion surgery,<sup>1,21,25</sup> the additional use of follow-up radiofrequency ablation and endoscopic foraminal decompression procedures may be deemed appropriate in up to one-third of lumbar endoscopy patients to manage contralateral or adjacent segment symptomatic stenosis and mechanical low back pain to maintain the treatment effect of the endoscopic index procedure.<sup>1,21,24</sup> Effectively, the end result is a staged management approach that we have advocated previously for the treatment of common lumbar pain generators that may affect patients' walking endurance differently depending on the functional context at the time when the spine care is delivered.<sup>26</sup> Mechanical back pain after endoscopic decompression, particularly in those patients where a hollow vacuum disc is found requiring additional medical, interventional, and surgical treatments, is not uncommon,<sup>27–30</sup> which is why we entertained the further use of spinal stabilization in conjunction with the lumbar endoscopic spinal surgery.

While both anterior<sup>31,32</sup> and posterior<sup>33</sup> column stabilization can be considered and are technically feasible to be performed endoscopically, the posterior column stabilization with interspinous process spacers (IPS) appears more attractive because of the (a) ease of minimally invasive implantation<sup>34–37</sup> and (b) vast extent of outcome literature on the clinical application of several implant systems in the treatment of claudication symptoms in patients with spinal stenosis, thereby catering to the individual surgeon's preference.<sup>38–44</sup> Furthermore, nearly all IPS systems are approved by the Food and Drug Administration (FDA) for stand-alone use obviating the need for posterior supplemental fixation,<sup>45–55</sup> which would, if necessary, complicate the scope of the endoscopic surgery, raise costs,<sup>51,56,57</sup> and take away from the attractiveness of the outpatient nature of the endoscopic surgery—a factor that could deter patients specifically seeking out endoscopic spine surgeons who do not subscribe to the routine use of pedicle screws. In contrast, there is currently only one interbody fusion system approved by the FDA for stand-alone anterior column stabilization.<sup>31,58</sup> Many other static and expandable interbody fusion systems suitable for the minimally invasive stabilizing anterior column reconstruction are available.<sup>58–65</sup> Still, they are not FDA approved to be used without supplemental use of posterior pedicle screw instrumentation.

The motivation for the conjunctive use of IPS with the endoscopic spinal decompression procedure stems from the desire to improve clinical outcomes with both methods and their associated durability. It is well known that the endoscopic lumbar decompression may rid patients of sciatica-type low back and leg pain as well as significantly improve endurance-limiting claudication symptoms but leave them with mechanical back pain that can be severe at times.<sup>3,66,67</sup> IPS are well known to produce good relief from these types of symptoms comparable to the various forms of open and minimally invasive lumbar decompression surgeries in the short term and midterm<sup>68–72</sup> while being associated with higher long-term reoperation rates than their surgical counterparts involving a formal decompression of the symptomatic compressed neural elements.<sup>36,44,73–76</sup>

In this meta-analysis, comparing numerical clinical outcomes with the directly visualized endoscopic and the nonvisualized indirect IPS decompression, the authors were interested in examining the associated effect sizes (ES) of commonly employed patient-reported outcome measures: the Oswestry Disability Index (ODI),<sup>77–79</sup> and the visual analog scales (VAS) for back and leg pain.<sup>80</sup> Many published meta-analyses

attempted to demonstrate clinical superiority of the endoscopic spinal surgery outcomes when compared to traditional translaminar microsurgical decompression techniques by selecting a few high quality studies, especially randomized controlled trials,<sup>81</sup> while excluding the findings from noncontrolled studies that are highly prevalent in the spinal surgery literature. Restricting meta-analyses by type of design or, for that matter, metrics of outcomes limits integration of clinically comparable data that might provide a comprehensive view on treatments and associated outcomes across settings.

To the authors' best knowledge, a meta-analysis comparison of results between lumbar endoscopic spinal decompression and IPS implantation that is agnostic to and thus supersedes study design and standardizes observed effects has not been reported. Instead of performing a narrowly focused meta-analysis based on a few randomized prospective, nonrandomized or single-group prospective studies, or well-controlled cross-sectional retrospective studies, we were interested in a broad investigation of the ES associated with reported clinical outcome improvements with lumbar endoscopic spinal and IPS surgery by extracting and analyzing the ODI and VAS means, SD, and the number of patients in each study. We performed additional subcategory, modifier, and wave analyses to cross-tabulate extracted ES by the length of follow-up, patients' age, the indication for surgery, the publication year, and the type of study design employed by the authors of the original studies. Ultimately, the authors intended to create a reference table of ES with the IPS and endoscopic spinal surgery to employ it in the comparative evaluation of the clinical merits of combining these 2 procedures.

## MATERIALS AND METHODS

### Search Strategy and Study Selection

The authors were interested in analyzing the ES data reported for commonly used numerical clinical outcome instruments including the ODI,<sup>77-79</sup> and VAS<sup>80</sup> for back and leg pain with lumbar endoscopic decompression and the IPS procedures. Therefore, we performed a meta-analysis of clinical studies on IPS and endoscopic decompression for lumbar herniated disc and spinal stenosis, reported here in alignment with the Preferred Reporting Items for Systematic Reviews and Meta-Analyses guidelines.<sup>82-89</sup> For this purpose, 3 authors (KUL, MYW, and ATY) searched the English-language literature on PubMed, Embase, Web of Science, and the Cochrane Database from 1 January 2000 to 31

December 2019 using "lumbar" and "herniated disc" or "spinal stenosis" and "endoscopic" and "ODI" and "VAS," or "interspinous" and "process" and "spacer" as keywords. They compared their searches to finalize the set of studies to be reviewed for possible inclusion. Discrepancies were resolved by consensus (Figure 1).

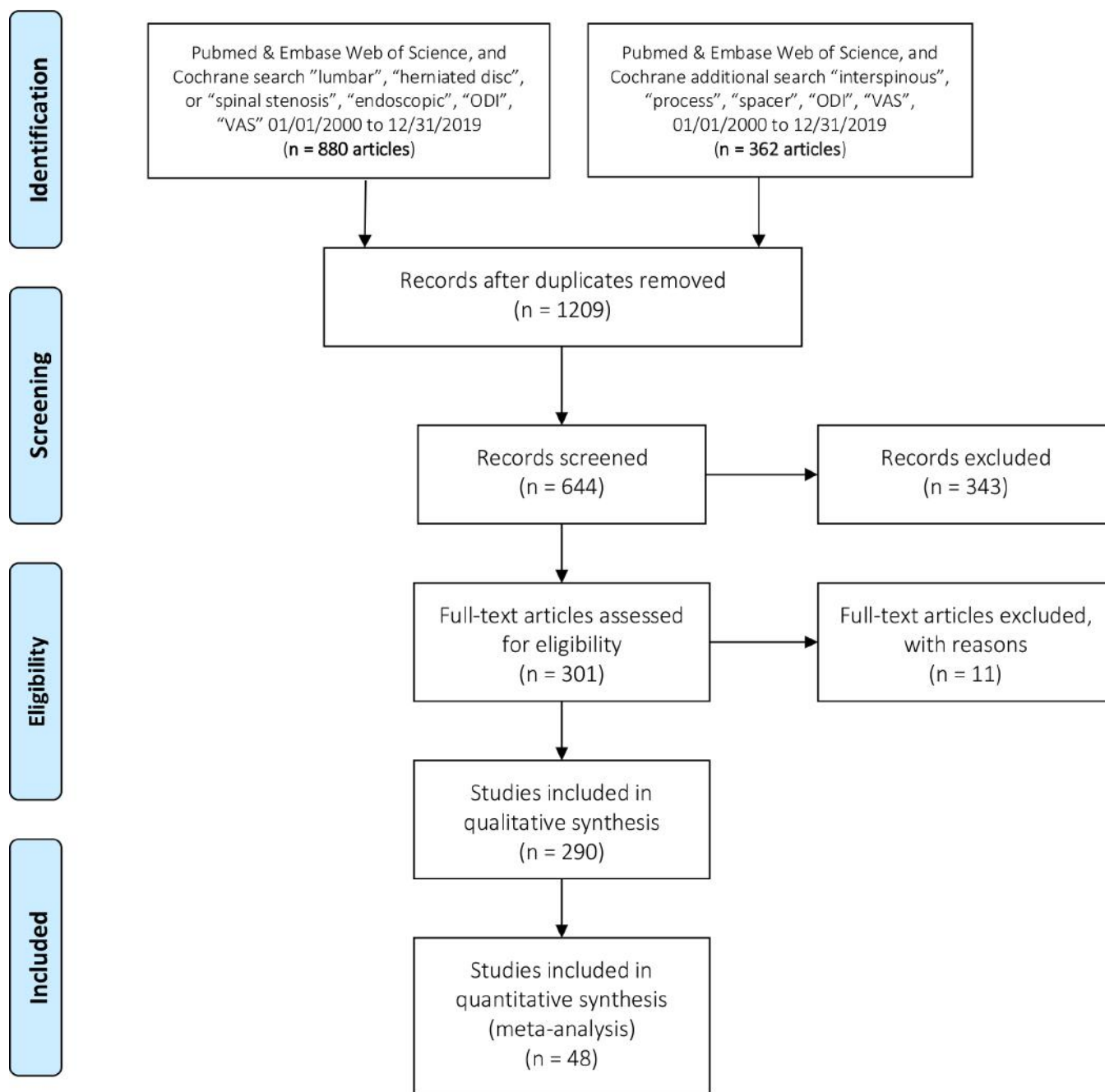
### Inclusion/Exclusion Criteria and Data Extraction

To be retained in the meta-analysis, studies needed to employ cross-sectional retrospective, prospective single treatment group, or randomized prospective multitreatment arm study designs comparing endoscopic with other minimally invasive spinal surgery techniques (MISST) including tubular retractor, and others. Studies needed to report IPS and endoscopic spinal surgery outcomes on patients suffering from symptoms related to lumbar herniated disc and foraminal or lateral recess stenosis utilizing the ODI, and the respective VAS scales for back and leg pain. IPS studies using the Zürich claudication score<sup>90-93</sup> were excluded since it is not a common outcome measurement tool in endoscopic spinal surgery studies. Only studies that reported the mean, the SD, and the sample size preoperatively and postoperatively for the ODI, VAS-BACK, and VAS-LEG were retained as this was essential information to calculate the effect metrics. Retrieved studies were further stratified by the type of endoscopic MISST access to the neural elements including transforaminal, interlaminar, or combinations, or variations of these techniques. Case reports, review articles, letters to the editor, editorials, short-term reports, and nonclinical studies, such as biomechanical and cadaveric studies, were excluded.

### Statistical Analysis

#### Database

We compiled a database of the included studies by recording the first study author and up to 2 additional coauthors (to differentiate between papers with same and similarly named first author), year of publication, study patients' mean age, and the preoperative baseline and the postoperative numerical ODI, VAS-BACK, and VAS-LEG scores at final available follow-up. Studies comparing multiple treatments were categorized by comparisons of "endoscopy" or "IPS" implantation vs "microsurgical" or "open" decompression. Additional moderators used in the analysis were study design (retrospective, prospective, and randomized prospective), indication for surgery (herniated disc radiculopathy, stenosis claudication, and discogenic pain), type



**Figure 1.** The Preferred Reporting Items for Systematic Reviews and Meta-Analyses flowchart of selected endoscopy and interspinous process spacer studies. ODI, Oswestry Disability Index; VAS, visual analog scale.

of MISST (endoscopy, open laminectomy, or tubular microdiscectomy), and IPS implantation.

### Standardization of Effects Across Study Designs

Clinical outcome data extracted from the articles included in this meta-analysis were the means and SDs of the VAS-BACK, the VAS-LEG, and the ODI, as well as the sample sizes preoperatively and postoperatively. The ES of postoperative improvements relative to preoperative status was calculated on the basis of the

number of enrolled study patients available at last follow-up using Cohen  $d$ :

$$d = (M_{\text{postop}} - M_{\text{preop}}) / SD_{\text{pooled}} \quad (\text{Eq. 1})$$

where  $M$  refers to the respective preoperative and postoperative means and  $SD_{\text{pooled}}$  to the pooled standard deviation of the preoperative and postoperative scores on the 3 scales of interest.<sup>94,95</sup> By convention,  $d = 0.2$  is considered a “small” ES,  $d = 0.5$  represents a “medium” ES, and  $d = 0.8$  a “large” ES. We applied  $d = 0.2$  as

the threshold, meaning that if the means of outcomes in endoscopy and IPS did not differ at a minimum by 0.2 SDs, the difference was considered trivial even if statistically significant.

### Analysis

The calculated ES, lower limit, upper limit, Higgins  $I^2$  statistic of heterogeneity ( $I^2$ ), variance ( $V$ ), SE, number of patients, and significance level (sig) of 95% CI were tabulated for all outcomes combined (ODI, VAS-BACK, and VAS-LEG) and for each outcome separately; and this across both surgery types and stratified by each surgery. Significance testing for differences between types of surgery was done using random effects analysis of variance of the studentized range statistic  $Q$  with separate estimates of  $T^2$  used in the between-group sum-of-squares estimation. These procedures were also applied to subanalyses by study design (retrospective, prospective, and randomized prospective) and surgery indication (herniated nucleus pulposus [HNP]; stenosis claudication). The average reduction of ODI, VAS-BACK, and VAS-LEG was compared to the reported and calculated minimal clinically important difference parameters of 3.0 for the VAS-LEGBACK and VAS-BACKLEG and 15 for ODI.<sup>96–101</sup> Statistical significance was set at  $\alpha$  of 0.05.

Each of the ODI, VAS-BACK, and VAS-LEG means of each study was weighted in inverse proportion of the respective variances and thus proportional to its precision. Heterogeneity among studies on an outcome of interest was examined by the Cochran  $Q$  test with the Higgins  $I^2$  statistic quantifying the percentage of variation across studies due to heterogeneity rather than chance. However, as patient-reported outcomes such as the ODI and, especially, the 2 VAS scales are known to be ordinal and inherently anchorless due to interindividual variation in thresholds and valuation, we considered the  $I^2$  as informative but not as cutoffs. To further offset this, all analyses applied a random effects model. Weighted metaregression plots were generated to evaluate associations between standardized ES and the potential moderator variables of patient age (in years) and follow-up (in months). Funnel plots (SE vs ES) were visually assessed for evidence of publication bias and by calculating the one-sided  $P$  value for intercept in Egger linear regression analysis and Kendall's  $\tau$ . Analyses were performed using Prometa 3, version 3.0 (Inter-novi, Borne, The Netherlands, 2015).

## RESULTS

### Search Results

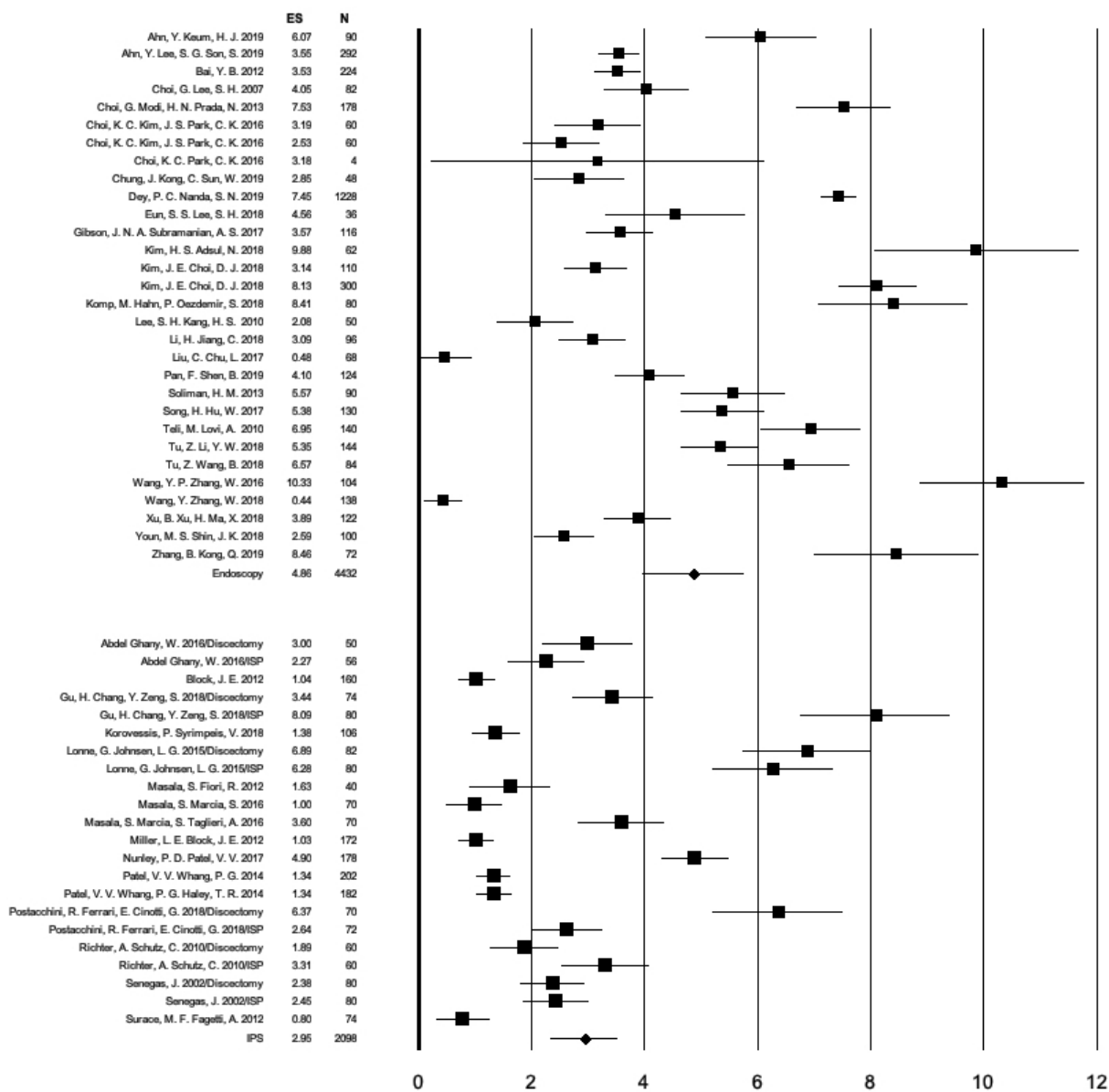
The first search yielded 880 publications, and the second search identified another 362 publications. Applying the inclusion/exclusion criteria, 48 publications were subjected to a full-text review resulting in the inclusion of 29 endoscopy<sup>5,7,30,102–127</sup> and 19 IPS studies in this meta-analysis (Figure 1).<sup>42,46,53,70,128–142</sup>

### Meta-Analysis Results for Clinical Outcomes

The pooled standardized ES when combining the ODI, VAS-BACK, and VAS-LEG data for the total sample size of 19,862 data sets from the 30 endoscopy studies and 18 interspinous spacer (ISP) studies revealed an overall ES of 0.877 (95% CI = 0.857–0.898). Stratifying by type of surgery, the pooled standardized ES across all outcomes were 0.877 (95% CI = 0.849–0.905;  $N$  = 10230) for endoscopic decompression and 0.863 (95% CI = 0.796–0.930;  $N$  = 8508) for IPS implantation, with the difference marginally failing statistical significance ( $P$  = 0.056).

In analyses by specific outcome, the pooled standardized ES for ODI ( $N$  = 6462) were 0.916 (95% CI = 0.891–0.943;  $N$  = 4364) for lumbar endoscopic decompression and 0.798 (95% CI = 0.713–0.883;  $N$  = 2098) for the IPS procedures; a difference that was statistically significant ( $P$  = 0.001) (Figure 2; Table 1). The pooled standardized ES for VAS-BACK ( $N$  = 3672) were 0.661 (95% CI = 0.585–0.738;  $N$  = 1574) for lumbar endoscopic decompression and 0.784 (95% CI = 0.644–0.923;  $N$  = 2098) for the IPS procedures; a difference that was not statistically significant ( $P$  = 0.187) (Figure 3; Table 1). The pooled standardized ES for VAS-LEG ( $N$  = 7890) were 0.885 (95% CI = 0.852–0.917;  $N$  = 4292) for lumbar endoscopic decompression and 0.851 (95% CI = 0.767–0.935;  $N$  = 3598) for the IPS procedures; a difference that was not statistically significant ( $P$  = 0.427) (Figure 4; Table 1).

Weighted regression analysis showed no significant ( $P$  = 0.289) association between pooled standardized ES and patient age (Figure 5); but did reveal an overall significant association ( $P$  = 0.026) between pooled standardized ES and follow-up (in months; Figure 6). Visual inspection of Figure 6 shows a large cluster of studies with follow-up of 24 months and many studies with longer follow-up compared to much fewer studies with follow-up less than 24 months. Further analysis revealed that follow-up of 24 months or more occurred in all of the ISP studies.



**Figure 2.** Forest plot of calculated Oswestry Disability Index (ODI) effect sizes (ES), 95% CI, and the number of patients enrolled in each of the endoscopic spinal surgery and interspinous process spacer (IPS) studies listed in alphabetical order according to the first author's name. The number of individual study patients is represented by the size of the square. The calculated pooled standardized ES for changes in ODI for the endoscopy studies was 0.917 (95% CI = 0.891–0.943). The corresponding ES for the IPS procedures was 0.798 (95% CI = 0.713–0.883). The analysis of variance Q test of difference showed a statistically higher ODI ES with endoscopy than with the IPS procedure ( $P = 0.001$ ).

Egger's regression yielded an intercept of 5.93 ( $P = 0.001$ ), and Kendall's  $\tau$  was  $-2.17$  ( $P = 0.030$ ) in analyses including all 3 outcome variables. The asymmetric funnel plot with several studies falling outside the expected area of SE vs ES further indicates moderate publication bias (Figure 7).

### Meta-Analysis by Modifiers

Subanalyses by study design (Table 2) revealed pooled standardized ES for the ODI ( $N = 6462$ ) of 0.884 (95% CI = 0.846–0.922;  $N = 3314$ ) for retrospective

studies, 0.890 (95% CI = 0.821–0.960;  $N = 1774$ ) for prospective studies, and 0.843 (95% CI = 0.729–0.957;  $N = 1374$ ) for randomized prospective studies (differences not significant,  $P = 0.742$ ). Pooled standardized ES for the VAS-BACK ( $N = 4386$ ) were 0.715 (95% CI = 0.587–0.843;  $N = 2560$ ) for retrospective studies, 0.425 (95% CI = 0.048–0.803;  $N = 284$ ) for prospective studies, and 0.806 (95% CI = 0.653–0.959;  $N = 1542$ ) for randomized prospective studies (differences not significant,  $P = 0.112$ ). Pooled standardized ES for the VAS-LEG ( $N = 7890$ ) were 0.866 (95% CI =

Table 1. List of endoscopy studies included into the meta-analysis with brief summary of study highlights.

No.	Authors	Year	Title	Reference	Study Highlights
1.	Ahn Y, Keum HI, et al <sup>5</sup>	2019	Transforaminal endoscopic decompression for lumbar lateral recess stenosis: an advanced surgical technique and clinical outcomes	<i>World Neurosurg.</i> 2019;125:e916–e924.	Retrospective 2-y follow-up study on 45 patients treated with transforaminal endoscopic decompression for lumbar lateral recess stenosis.
2.	Ahn Y, Lee SG, et al <sup>102</sup>	2019	Transforaminal endoscopic lumbar discectomy vs open lumbar microdiscectomy: a comparative cohort study with a 5-year follow-up	<i>Pain Physician.</i> 2019;22:295–304.	Long-term prospective outcome analysis of PELD vs microdiscectomy on 335 with 5-y follow-up.
3.	Bai YB, Xu L, et al <sup>103</sup>	2012	Diagnosis and treatment of lumbar disc herniation by discography and percutaneous transforaminal endoscopic surgery	<i>Zhonghua Yi Xue Za Zhi.</i> 2012;92:3350–3353.	Retrospective analysis (26 mo) of 119 LDH patients by discography and transforaminal PELD surgery.
4.	Choi G, Lee SH, et al <sup>104</sup>	2007	Percutaneous endoscopic discectomy for extraforaminal lumbar disc herniations: extraforaminal targeted fragmentectomy technique using working channel endoscope	<i>Spine (Phila Pa 1976).</i> 2007;32:E93–E99.	A retrospective analysis (34.1 mo follow-up) of 41 patients with soft lumbar extraforaminal disc herniations treated by endoscopic extraforaminal approach under local anesthesia.
5.	Choi G, Modi HN, et al <sup>105</sup>	2013	Clinical results of XMR-assisted percutaneous transforaminal endoscopic lumbar discectomy	<i>J Orthop Surg Res.</i> 2013;8:14.	Prospective study on 89 patients (2-y follow-up) undergoing PELD for LDH in an operative suite equipped with fluoroscopic and magnetic resonance imaging.
6.	Choi KC, Kim JS, et al <sup>106</sup>	2016	Percutaneous endoscopic lumbar discectomy as an alternative to open lumbar microdiscectomy for large lumbar disc herniation	<i>Pain Physician.</i> 2016;19:E291–E300.	Retrospective observational study (2-y follow-up) on 20 endoscopic and 23 open lumbar discectomy patients.
7.	Choi KC and Park CK <sup>107</sup>	2016	Percutaneous endoscopic lumbar discectomy for L5-S1 disc herniation: consideration of the relation between the iliac crest and L5-S1 disc	<i>Pain Physician.</i> 2016;19:E301–E308.	Retrospective study on 51 patients (2-y follow-up) treated either with transforaminal PELD or interlaminar PELD.
8.	Chung J, Kong C, et al <sup>7</sup>	2019	Percutaneous endoscopic lumbar foraminoplasty for lumbar foraminal stenosis of elderly patients with unilateral radiculopathy: radiographic changes in magnetic resonance images	<i>J Neurol Surg A Cent Eur Neurosurg.</i> 2019;80:302–311.	Retrospective study (2-y follow-up) of 24 patients over 65 y of age who underwent percutaneous endoscopic lumbar foraminoplasty to treat unilateral radiculopathy caused by LFS.
9.	Dey PC and Nanda SN <sup>108</sup>	2019	Functional outcome after endoscopic lumbar discectomy by Destandau's technique: a prospective study of 614 patients	<i>Asian Spine J.</i> 2019;13:786–792.	Retrospective study on 614 patients who underwent endoscopic lumbar discectomy using Destandau endospine system after a minimum follow-up of 12 mo and maximum up to 54 mo.
10.	Eun SS, Lee SH, et al <sup>109</sup>	2018	Transforaminal percutaneous endoscopic lumbar discectomy for downmigrated disk herniations: lever-up, rotate, and tilt technique	<i>J Neurol Surg A Cent Eur Neurosurg.</i> 2018;79:163–168.	Retrospective study (2-y follow-up) of 18 patients who underwent transforaminal PELD.
11.	Gibson JNA, et al <sup>110</sup>	2017	A randomized controlled trial of transforaminal endoscopic discectomy vs microdiscectomy	<i>Eur Spine J.</i> 2017;26:847–856.	Prospective trial on 143 patients, age 25–70 y with single-level lumbar prolapse and radiculopathy with 70 randomized transforaminal PELD under conscious sedation and 70 to microdiscectomy under general anesthesia.
12.	Kim HS, Adsul N, et al <sup>111</sup>	2018	A mobile outside-in technique of transforaminal lumbar endoscopy for lumbar disc herniations	<i>J Vis Exp.</i> 2018;(138):57999.	Prospective study on mobile outside-in treatment of LDH in 184 consecutive patients with unilateral lower limb radiculopathy—19 ± 6 mo follow-up.
13.	Kim JE and Choi DJ <sup>112</sup>	2018	Biportal arthroscopic spinal surgery (BASS) with 30 degrees arthroscopy for far lateral approach of L5-S1 - technical note	<i>J Orthop.</i> 2018;15:354–358.	Retrospective study on 12 patients with far lateral approach of biportal arthroscopic technique using 30 degrees arthroscopy for foraminal decompression of L5-S1.
14.	Komp M, Hahn P, et al <sup>113</sup>	2014	Operation of lumbar zygapophysial joint cysts using a full-endoscopic interlaminar and transforaminal approach: prospective 2-year results of 74 patients	<i>Surg Innov.</i> 2014;21:605–614.	Prospective study (2-y follow-up) of 74 full-endoscopic interlaminar and transforaminal PELD patients treat for lumbar z-joint cysts.
15.	Lee SH and Kang HS <sup>10</sup>	2010	Percutaneous endoscopic laser annuloplasty for discogenic low back pain	<i>World Neurosurg.</i> 2010;73:198–206.	Retrospective study on 37 patients treated at a single-level laser-assisted spinal endoscopy vs percutaneous endoscopic laser annuloplasty with a mean follow-up of 9.7 mo.
16.	Lewandrowski KU, de Carvalho PST, et al <sup>127</sup>	2020	Outcomes with transforaminal endoscopic vs percutaneous laser decompression for contained lumbar herniated disc: a survival analysis of treatment benefit	<i>J Spine Surg.</i> 2020;6:S84–S99.	Retrospective study of 248 patients consisting of 162 patients in the endoscopic group and 86 patients in the laser discectomy group with average 43.5 mo follow-up.
17.	Li H, Jiang C, et al <sup>114</sup>	2018	Comparison of MED and PELD in the treatment of adolescent lumbar disc herniation: A 5-year retrospective follow-up	<i>World Neurosurg.</i> 2018;112:e255–e260.	Retrospective study (48 mo follow-up) comparing the efficacy and safety of MED (30 patients) and PELD (48 patients) in the treatment of ALDH.
18.	Liu C, Chu L, et al <sup>115</sup>	2017	Percutaneous endoscopic lumbar discectomy for highly migrated lumbar disc herniation	<i>Pain Physician.</i> 2017;20:E75–E84.	Retrospective study (3 mo follow-up) on 73 patients with highly migrated LDH treated with PELD comparing 3 approaches.

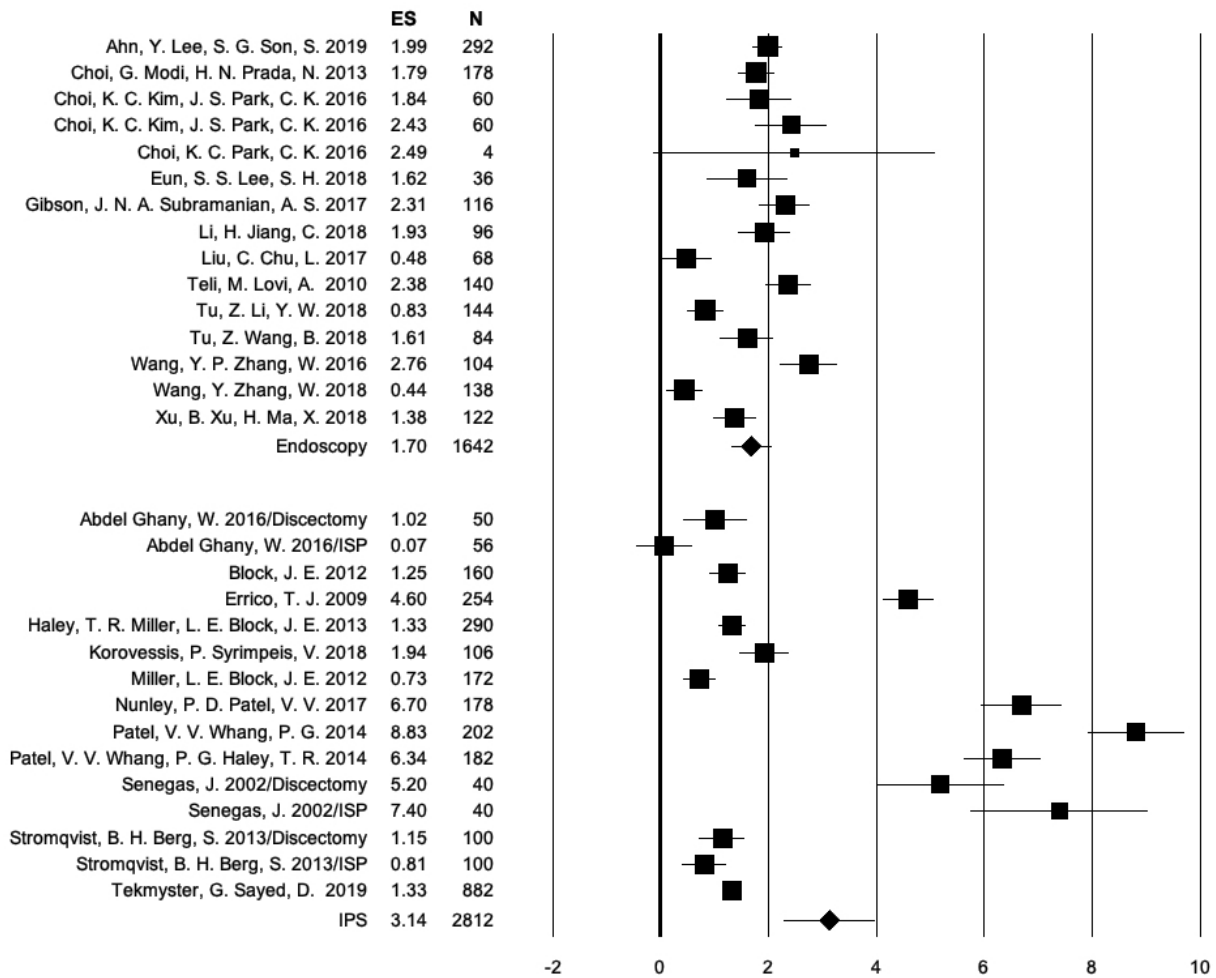
Continued

**Table 1. Continued**

No.	Authors	Year	Title	Reference	Study Highlights
19.	Pan F, Shen B, et al <sup>116</sup>	2016	Transforaminal endoscopic system technique for discogenic low back pain: a prospective cohort study	<i>Int J Surg</i> 2016;35:134–138.	Retrospective consecutive case series with 62 patients with L1-level discogenic low back pain with 26.8 ± 4.2 mo follow-up.
20.	Soliman HM <sup>117</sup>	2013	Irrigation endoscopic discectomy: a novel percutaneous approach for lumbar disc prolapse	<i>Eur Spine J.</i> 2013;22:1037–1044.	Prospective case series of 43 patients with uncontained LDH underwent irrigation endoscopic discectomy surgery with 24 mo follow-up.
21.	Song H, Hu W, et al <sup>118</sup>	2017	Percutaneous endoscopic interlaminar discectomy of L5-S1 disc herniation: a comparison between intermittent endoscopy technique and full endoscopy technique	<i>J Orthop Surg Res.</i> 2017;12:162.	Retrospective study comparing full endoscopy technique (65 patients) or intermittent endoscopy technique (61 patients) with average 27 mo follow-up.
22.	Teli M, Lovi A, et al <sup>119</sup>	2017	Higher risk of dural tears and recurrent herniation with lumbar microendoscopic discectomy	<i>Eur Spine J.</i> 2010;19:443–450.	Randomized controlled trial of 240 patients was randomized to microendoscopic (group 1), micro (group 2), or open (group 3) discectomy with minimum 2-y follow-up.
23.	Tu Z, Li YW, et al <sup>120</sup>	2010	Clinical outcome of full-endoscopic interlaminar discectomy for single-level lumbar disc herniation: a minimum of 5-year follow-up	<i>Pain Physician.</i> 2017;20:E425–E430.	Retrospective study of 152 patients with single-level LDH located at either L4-L5 or L5-S1 who underwent either FEID (72 patients) or MED (80 patients) with <5-y follow-up.
24.	Tu Z, Wang B, et al <sup>121</sup>	2018	Early experience of full-endoscopic interlaminar discectomy for adolescent lumbar disc herniation with sciatic scoliosis	<i>Pain Physician.</i> 2018;21:E63–E70.	Retrospective case series of patients under age 20 with single-level ALDH with and without scoliosis treated with FEID. Average follow-up 39 mo.
25.	Wang Y, Zhang W, et al <sup>122</sup>	2018	Transforaminal endoscopic discectomy for treatment of central disc herniation: surgical techniques and clinical outcome	<i>Pain Physician.</i> 2018;21:E113–E123.	Retrospective 2-y follow-up study of 69 consecutive patients treated with transforaminal PELD central disc herniation.
26.	Wang YP, Zhang W, et al <sup>123</sup>	2016	Evaluation of transforaminal endoscopic discectomy in treatment of obese patients with lumbar disc herniation	<i>Med Sci Monit.</i> 2016;22:2513–2519.	Prospective study of 69 obese patients with LDH (35 men and 34 women; age range, 24–43 y) treated for LDH with PELD.
27.	Xu B, Xu H, et al <sup>124</sup>	2018	Bilateral decompression and intervertebral fusion via unilateral fenestration for complex lumbar spinal stenosis with a mobile microendoscopic technique	<i>Medicine (Baltimore).</i> 2018;97:e9715.	Retrospective 3-y follow-up study on 61 patients with complex lumbar spinal stenosis (lumbar canal stenosis combined with degenerative spondylolisthesis, instability, and scoliosis) treated with Destandau-type mobile microendoscopic discectomy.
28.	Youn MS, Shin JK, et al <sup>125</sup>	2018	Endoscopic posterior decompression under local anesthesia for degenerative lumbar spinal stenosis	<i>J Neurosurg Spine.</i> 2018;29:661–666.	Retrospective study of 50 patients (28 women and 22 men) treated for LDH with endoscopic posterior decompression under local anesthesia followed up to 24 mo postoperatively.
29.	Zhang B, Kong Q, et al <sup>126</sup>	2019	Short-term effectiveness of percutaneous endoscopic transforaminal bilateral decompression for severe central lumbar spinal stenosis	<i>Zhongguo Xiu Fu Chong Jian Wai Ke Za Zhi.</i> 2019;33:1399–1405.	Retrospective study on effectiveness and safety of bilateral transforaminal bilateral PELD decompression for severe central lumbar spinal stenosis in 44 patients with average follow-up of 24.8 mo.

Abbreviations: ALDH, adolescent lumbar disc herniation; FEID, full-endoscopic interlaminar discectomy; LDH, lumbar disc herniation; MED, minimally endoscopic discectomy; PELD, percutaneous endoscopic lumbar discectomy.





**Figure 3.** Forest plot of calculated visual analog scale (VAS)-BACK effect sizes (ES), 95% CI, and the number of patients enrolled in each of the endoscopic spinal surgery and interspinous process spacer (IPS) studies listed in alphabetical order according to the first author's name. The number of individual study patients is represented by the size of the square. The calculated pooled standardized ES for changes in VAS-BACK for the endoscopy studies was 0.661 (95% CI = 0.585–0.738). The corresponding ES for the IPS procedures was 0.784 (95% CI = 0.644–0.923). The analysis of variance Q test of difference indicated that this difference in VAS-BACK ES was not statistically significant ( $P = 0.187$ ).

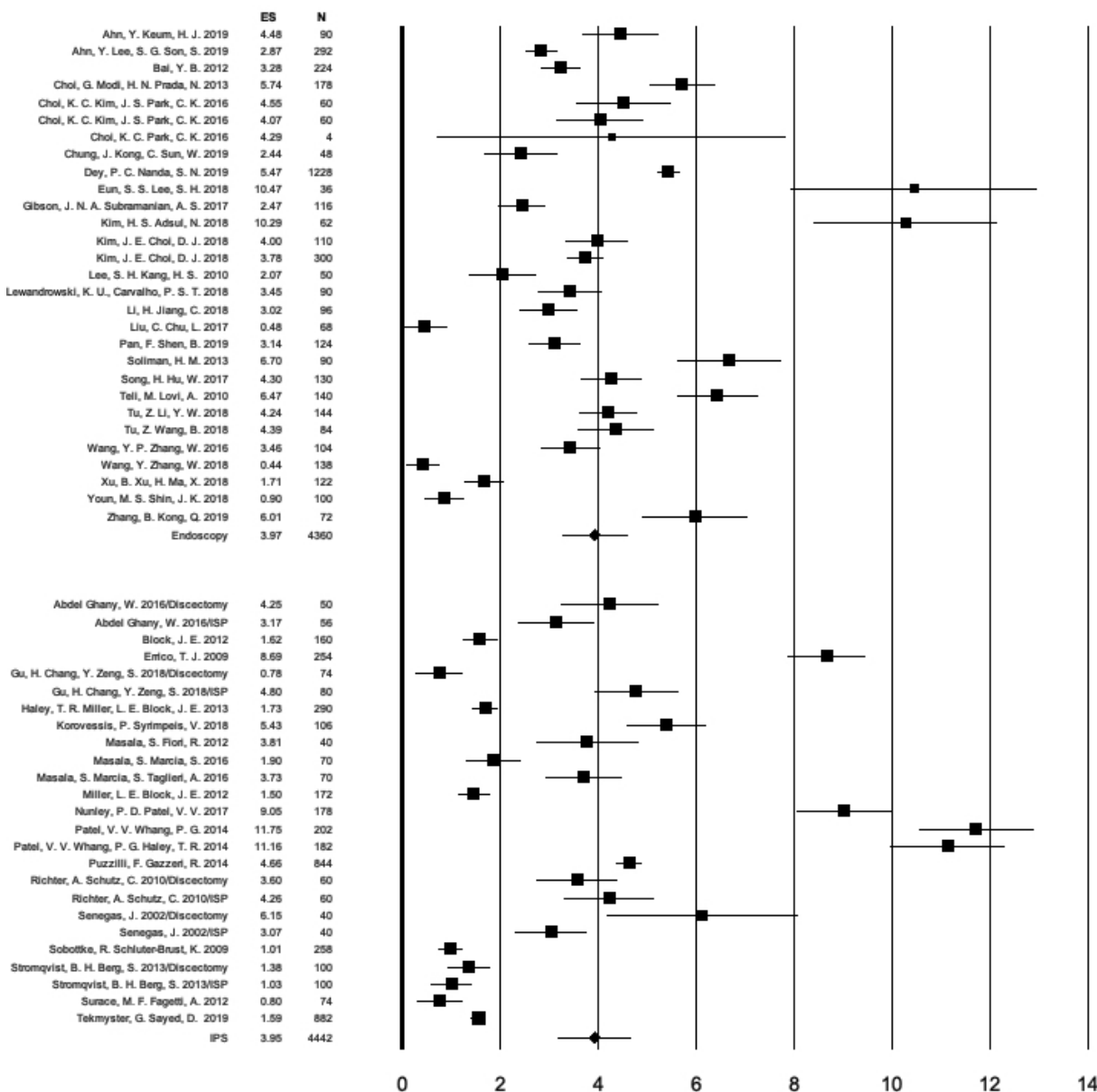
0.819–0.912;  $N = 4716$ ) for retrospective studies, 0.912 (95% CI = 0.885–0.938;  $N = 1632$ ) for prospective studies, and 0.860 (95% CI = 0.733–0.987;  $N = 1542$ ) for randomized prospective studies (differences not significant,  $P = 0.175$ ).

Subanalyses by surgery indication (Table 3) yielded pooled standardized ES for the ODI ( $N = 2884$ ) of 0.920 (95% CI = 0.862–0.977;  $N = 880$ ) for HNP radiculopathy and 0.815 (95% CI = 0.722–0.907;  $N = 2004$ ) for stenosis claudication (differences not significant,  $P = 0.076$ ). Pooled standardized ES for the VAS-BACK ( $N = 3286$ ) were 0.532 (95% CI = 0.271–0.794;  $N = 506$ ) for HNP radiculopathy and 0.694 (95% CI = 0.514–0.874;  $N = 2780$ ) for stenosis claudication (differences not significant,  $P = 0.307$ ). Pooled standardized ES for the VAS-LEG ( $N = 4464$ ) were 0.868 (95% CI = 0.769–0.966;  $N = 880$ ) for HNP radiculopathy and 0.830 (95%

CI = 0.736–0.874;  $N = 3584$ ) for stenosis claudication (differences not significant,  $P = 0.869$ ).

### Individual Studies Results and Minimal Clinically Important Difference

Preoperative baseline means (SD) were 59.34 (SD 12.67) for the ODI, 4.90 (SD 1.89) for the VAS-BACK, and 7.22 for the VAS-LEG (SD 1.90). Improvements after endoscopic surgery were an ODI reduction of 46.25 (SD 6.10), VAS-BACK reduction of 3.29 (SD 0.65), and VAS-LEG reduction of 5.77 (SD 0.66). The mean (SD) percent changes of ODI, VAS-BACK, and VAS-LEG ratings at a follow-up of 2 years or longer after endoscopic decompression were 77.94% (SD 10.28%), 67.14% (SD 13.26%), and 79.71% (SD 9.14%), respectively. The mean (SD) percent change of ODI, VAS-BACK, and VAS-LEG at a follow-up of



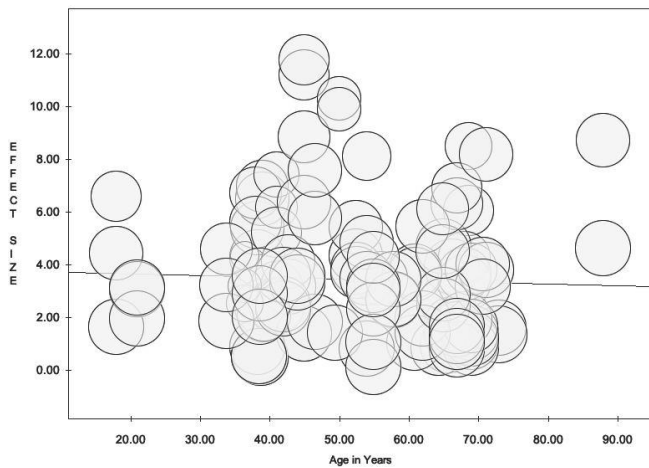
**Figure 4.** Forest plot of calculated visual analog scale (VAS)-LEG effect sizes (ES), 95% CI, and the number of patients enrolled in each of the endoscopic spinal surgery and interspinous process spacer (IPS) studies listed in alphabetical order according to the first author's name. The number of individual study patients is represented by the size of the square. The calculated pooled standardized ES for changes in VAS-LEG for the endoscopy studies was 0.885 (95% CI = 0.852–0.917). The corresponding ES for the IPS procedures was 0.851 (95% CI = 0.767–0.935). The analysis of variance Q test of difference indicated that this difference in VAS-LEG ES was not statistically significant ( $P = 0.427$ ).

2 years or longer after ISP implantation was 68.31% (SD 9.39%), 58.12% (SD 11.51%), and 71.21% (SD 11.26%), respectively. The ODI, VAS-BACK, and VAS-LEG reductions producing the ES calculations listed in Tables 1–3 were the equivalent of 3 times reported minimal clinically important differences.<sup>84</sup>

## DISCUSSION

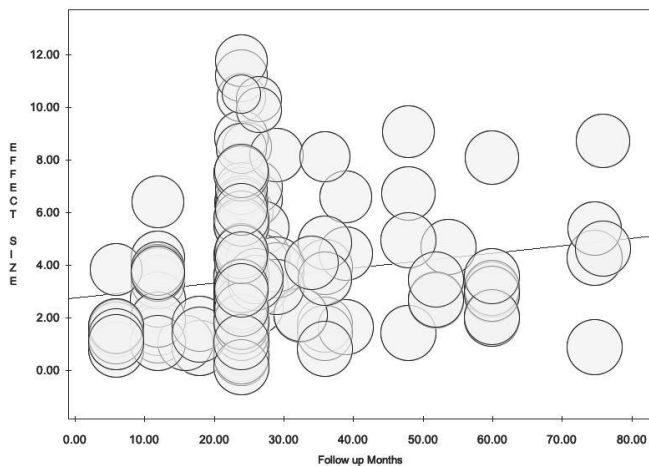
One might ask, what is the point of combining lumbar spinal endoscopy with the placement of an IPS? To those who routinely perform both types of surgeries,

the answer is quite obvious. Both procedures have shortcomings that are far outweighed by their advantages but in some cases prompt new interventional and surgical management following the index procedure. In short, spinal endoscopy is attractive to many patients because of the small incisions, low complication rates,<sup>22,23</sup> and its outpatient nature. The staged management approach to common lumbar spinal pain generators the authors advocate for<sup>143</sup> translates into minor concise surgeries on validated pain generators, while ignoring many other structural problems not contributing to the patient's

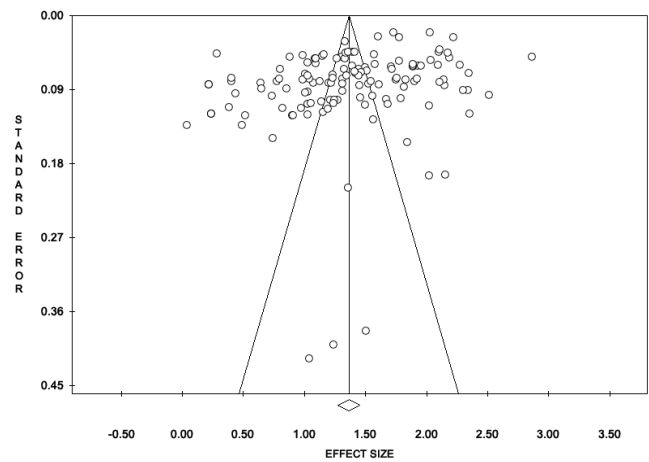


**Figure 5.** Meta-analysis regression plot of effect size vs age in years using random effects model showed no significant correlation ( $P = 0.289$ ).

pain syndrome in the current context of spine care at the time when the care is delivered. Endoscopy’s downside is persistent mechanical low back pain, which in many patients stems from facet arthropathy or severely degenerated vacuum discs. IPS implants, on the other hand, are attractive because of the simplicity of implantation and the low perioperative burden to spinal stenosis patients who often suffer from poorly controlled medical comorbidities.<sup>76</sup> The short-term and midterm track record of IPS to improve claudication symptoms is favorable,<sup>41,44,48,53,56,68–70,128,129,144–148</sup> but the reoperation rate is higher than with formal open lumbar decompression surgery.<sup>44,48,52,53,55,74,75,128,139,146,148–154</sup> IPS procedures also have been demonstrated to relieve mechanical back pain effectively.<sup>71</sup> Hence, combining lumbar spinal endoscopy and IPS procedures may ultimately improve clinical outcomes with these 2



**Figure 6.** Meta-analysis plot of effect size (ES) vs follow-up in months using random effects model showed a statistically significantly higher proportion of studies (all of the interspinous spacer studies) with either 24 months follow-up or more with higher ES numbers in the longer follow-up studies ( $P = 0.026$ ).



**Figure 7.** Funnel plot assessing publication bias (SE vs effect size).

nonfusion technologies—a strategy that fits well within the scope of cost-saving policies of modern healthcare systems. This dynamic was the underlying motivation of this meta-analysis, which accompanies an original study and review article that is published alongside this meta-analysis in this special focus issue of the International Journal of Spine Surgery.

We took a broad approach to extract outcome data from original studies on endoscopic and IPS spinal surgeries to afford the reader the ability to better compare their clinical benefit concerning indication for surgery and burden to the patient in an across-the-board normalized comparison. Highlighting differences in outcomes between directly visualized endoscopic and the indirect IPS decompression by reporting the standardized ES has several advantages, including the ability to test report statistical tests for group comparison. Standardized ES quantify the gradient of difference between the treatment groups rather than confounding this difference with sample size and statistical power.<sup>155–157</sup> As eq. 1 above shows,  $d$  is calculated by subtracting the mean of one group from the mean of another group and dividing it by the pooled SD. Despite being standardized and simple, the ES is rarely used in the comparison and discussion of clinical outcomes between treatments.<sup>155</sup> As we showed here, the  $d$  metric can be highly useful as a measure of overlap of treatment benefit between spinal endoscopic and IPS procedures—a form of data interpretation we employed in this study to illustrate the various aspects of clinical benefit between the types of lumbar decompression procedures.

We chose the meta-analysis approach to calculating ES since it overcomes the common problem of not knowing the SD of the population from which the different treatment groups were sampled by estimating it

**Table 2.** List of interspinous process spacer studies included into the meta-analysis with brief summary of study highlights.

#	Authors	Year	Title	Reference	Study Highlights
1.	Abdel Ghany W, Amer A, et al <sup>128</sup>	2016	Evaluation of interspinous spacer outcomes in degenerative lumbar canal stenosis: clinical study	<i>World Neurosurg.</i> 2016;9(5):556–564 e553.	Prospective 12 mo study comparing 28 decompression. In the second group, 25 patients underwent decompressive laminectomy.
2.	Errico TJ, Kamerlink JR, et al <sup>70</sup>	2009	Survivorship of coflex interlaminar-interspinous implant	<i>SAS J.</i> 2009;3:59–67.	Retrospective study of 127 patients underwent placement of a coflex implant for various stenosis-related indications with a mean follow-up of 6.3 y.
3.	Gu H, Chang Y, et al <sup>131</sup>	2018	Wallis interspinous spacer for treatment of primary lumbar disc herniation: three-year results of a randomized controlled trial	<i>World Neurosurg.</i> 2018;120:e1331–e1336.	Prospective, single-center, randomized, controlled clinical trial comparing the postoperative results of lumbar discectomy with and without the Wallis implant. A total of 77 patients were included in the randomized study group, with 40 undergoing lumbar discectomy with Wallis implant insertion (Wallis group) and 37 undergoing lumbar discectomy alone (control group).
4.	Haley TR, Miller LE, et al <sup>129</sup>	2013	Midterm outcomes of a prospective randomized controlled trial of interspinous spacer treatment for moderate lumbar spinal stenosis	<i>PM&amp;R.</i> 2013;S289.	Prospective, randomized, controlled, IDE trial. Setting: 23 hospitals in the United States. Participants: 145 patients with intermittent neurogenic claudication secondary to moderate LSS and unresponsive to conservative care.
5.	Korovessis P, Syrimpeis V, et al <sup>130</sup>	2018	PEEK vs silicon interspinous spacer for reduction of supradjacent segment degeneration following decompression and short-segment instrumentation for degenerative lumbar spinal stenosis	<i>Adv Orthop.</i> 2018;2018:1623647.	Interventions: Patients were randomly treated with ISP implant (Superion 75; X-Stop 70) and followed for 18 mo. A consecutive retrospective study of 55 patients on incidence of ASD and spinopelvic balance in short lumbosacral instrumentation for degenerative LSS with IS placement in the supradjacent segment and its interaction with spinopelvic balance: 17 patients received PEEK IS; 18 received Silicon IS and were compared with 20 controls without any ISP.
6.	Lønne G, Johnsen LG, et al <sup>132</sup>	2015	Comparing cost-effectiveness of X-Stop with minimally invasive decompression in lumbar spinal stenosis: a randomized controlled trial	<i>Spine (Phila Pa 1976).</i> 2015;40(5):514–520.	Randomized clinical trial of 96 patients with 1-level or 2-level LSS, and 2-y follow-up to compare the cost-effectiveness of X-Stop to minimally invasive decompression in patients with symptomatic LSS.
7.	Masala S, Fiori R, et al <sup>133</sup>	2012	Percutaneous decompression of lumbar spinal stenosis with a new interspinous device	<i>Cardiovasc Intervent Radiol.</i> 2012;35:368–374.	Retrospective 6-mo follow-up study with the Falena ISP implanted at a single level in 26 patients (17 men; mean age, 69 (range, 54–82 y)) suffering degenerative LSS.
8.	Masala S, Marcia S, et al <sup>42</sup>	2016	Degenerative lumbar spinal stenosis treatment with Aperius PerCLID system and Falena(R) interspinous spacers: 1-year follow-up of clinical outcome and quality of life.	<i>Interv Neuro Radiol.</i> 2016;22:217–226.	Retrospectively 12-mo follow-up study of 24 patients (20 men and 4 women; 61 ± 9 y old), treated with an implantation of the Aperius, PerCLID system, and from 35 patients (29 men and 6 women; 65 ± 9 y old) treated with the Falena interspinous device.
9.	Miller LE and Block JE <sup>46</sup>	2012	Interspinous spacer implant in patients with lumbar spinal stenosis: preliminary results of a multicenter, randomized, controlled trial	<i>Pain Res Treat.</i> 2012;2012:823509.	A prospective, randomized, controlled trial 6-mo follow-up IDE trial of ISP (Superion) vs those treated with an FDA-approved spacer (X-Stop). A total of 166 patients with moderate LSS unresponsive to conservative care were treated randomly with the Superion (n = 80) or X-Stop (n = 86) ISP.
10.	Nunley PD, Patel VV, et al <sup>134</sup>	2017	Superion interspinous spacer treatment of moderate spinal stenosis: 4-year results	<i>World Neurosurg.</i> 2017;104:279–283.	Prospective 4-y clinical outcomes study in patients with intermittent neurogenic due to moderate LSS treated with minimally invasive standalone ISP decompression using the Superion device. The data were extracted from a randomized, controlled FDA IDE trial.
11.	Patel VV, Whang PG, et al <sup>53</sup>	2014	Two-year clinical outcomes of a multicenter randomized controlled trial comparing two interspinous spacers for treatment of moderate lumbar spinal stenosis	<i>BMC Musculoskelet Disord.</i> 2014;15:221.	Prospective, multicenter, randomized, 2-y controlled trial in patients with moderate LSS treated with the Superion (experimental) or the X-Stop, an FDA-approved ISP (control). A total of 250 patients with moderate LSS unresponsive to conservative care were randomly allocated to treatment with the experimental (n = 123) or control (n = 127) ISP.
12.	Postacchini R, Ferrari E, et al <sup>135</sup>	2011	Aperius interspinous implant vs open surgical decompression in lumbar spinal stenosis	<i>Spine J.</i> 2011;11:933–939.	Prospective comparative cohort 12 mo study of patients with moderate or severe LSS treated with the Aperius or by open decompression.
13.	Puzzilli F, Gazzeri R, et al <sup>44</sup>	2014	Interspinous spacer decompression (X-Stop) for lumbar spinal stenosis and degenerative disk disease: a multicenter study with a minimum 3-year follow-up	<i>Clin Neurol Neurosurg.</i> 2014;124:166–174.	Prospective 36 mo study comparing clinical outcomes of 422 ISP patients (X-Stop) to 120 control cases were managed conservatively.
14.	Richter A, Schutz C, et al <sup>136</sup>	2010	Does an interspinous device (Coflex) improve the outcome of decompressive surgery in lumbar spinal stenosis? One-year follow up of a prospective case control study of 60 patients	<i>Eur Spine J.</i> 2010;19:283–289.	Prospective 12 mo study of 60 patients comparing 1-level or 2-level symptomatic LSS decompressive surgery to LSS decompressive surgery (30 patients) and additional implantation of the Coflex ISP (30 patients).
15.	Senegas J <sup>137</sup>	2002	Mechanical supplementation by non-rigid fixation in degenerative intervertebral lumbar segments: the Wallis system	<i>Eur Spine J.</i> 2002;11(suppl 2):S164–S169.	A 3-y prospective cohort study comparing discectomy alone with discectomy and ISP implantation using Wallis.

*Continued*

**Table 2. Continued**

#	Authors	Year	Title	Reference	Study Highlights
16.	Sobottke R, Schluter-Brust K, et al <sup>142</sup>	2009	Interspinous implants (X-Stop, Wallis, Diam) for the treatment of LSS: is there a correlation between radiological parameters and clinical outcome?	<i>Eur Spine J.</i> 2009;18:1494–1503.	Retrospective comparative study of 129 consecutive patients with LSS treated with X-Stop, Wallis, or Diam.
17.	Surace MF, Fagetti A, et al <sup>138</sup>	2012	Lumbar spinal stenosis treatment with Aperius percid interspinous system	<i>Eur Spine J.</i> 2012;21(suppl 1): S69-S74.	Prospective cohort, 18 mo study of 37 patients (20 men and 17 women) with mean age of 64.3 y treated with Aperius and PercLID ISP foraminial stenosis.
18.	Stromqvist BH, Berg S, et al <sup>139</sup>	2013	X-Stop vs decompressive surgery for lumbar neurogenic intermittent claudication: randomized controlled trial with 2-year follow-up.	<i>Spine (Phila Pa 1976).</i> 2013;38:1436–1442.	Prospective comparative 18 mo cohort study of 100 patients with symptomatic 1-level or 2-level LSS; 50 in the X-Stop group and 50 in the decompression group.
19.	Tekmyster G, Sayed D, et al <sup>140</sup>	2019	Interspinous process decompression with the Superion® spacer for lumbar spinal stenosis: real-world experience from a device registry	<i>Med Devices (Auckl).</i> 2019;12:423–427.	Retrospective study of clinical outcomes with Superion. Indirect decompression system in 1426 LSS patients with intermittent neurogenic claudication treated by 316 physicians at 86 clinical sites in the United States participated.

Abbreviations: ASD, adjacent segment degeneration; FDA, Food and Drug Administration; IDE, investigational device exemption; ISP, interspinous spacer; LSS, lumbar spinal stenosis.

**Table 3.** Analysis of effect size, heterogeneity, and ANOVA testing of difference by surgery type.

Type of Surgery		Number of Studies Included in This Analysis (Multiple Study Groups Possible)	Effect Sizes	Lower Limit	Upper Limit	Higgins I2 Statistic of Heterogeneity	Variance	SE	N
Oswestry Disability Index	Endoscopy	29	0.912	0.891	0.943	0%	0.0002	0.0132	4364
	Interspinous process spacer	22	0.798	0.713	0.883	0%	0.0019	0.0435	2098
						<i>P</i> = 0.001	Total <i>N</i> patients		6462
VAS-BACK	Endoscopy	14	0.661	0.585	0.734	0%	0.0015	0.0389	1574
	Interspinous process spacer	15	0.784	0.644	0.923	0%	0.0050	0.0711	2098
						<i>P</i> = 0.187	Total <i>N</i> patients		<b>3672</b>
VAS-LEG	Endoscopy	28	0.885	0.852	0.917	0%	0.000	0.017	4292
	Interspinous process spacer	24	0.851	0.767	0.935	0%	0.002	0.043	3598
						<i>P</i> = 0.427	Total <i>N</i> patients		<b>7890</b>

Abbreviations: ANOVA, analysis of variance; VAS, visual analog scale.

by pooling data from the treatment groups of various studies. The ES derived from preoperative and postoperative disability data (ODI, VAS-BACK, and VAS-LEG) from a total of 48 studies were, in general, large.<sup>95</sup> Importantly, they tended to exceed established reference data set of ES with the endoscopic and the IPS procedures by a multiple of about 3, which to the authors' best knowledge has not been published.

Despite the majority of patients treated with endoscopic or IPS surgery were between the ages of 40 and 70 years, patient age was not found to impact clinical outcomes (Figure 5). Further, and important given the general challenge in surgery for randomized (blinded) clinical trials, neither did the type of study design impact ES—though with one, albeit positive, exception: the ES calculated for the VAS-BACK underscored the long-term (2 years or more postsurgery) benefit of IPS in relief of back pain (Figure 6), especially in higher quality randomized prospective trials with therefore lower risk of bias. When stratifying by surgical indication as a modifier, ODI and VAS-LEG ES for the surgery indication of spinal stenosis-related neurogenic claudication were

similar and both were higher than the corresponding ES for VAS-BACK (Table 4). The overlap in the precision (95% CI) estimates between the VAS-LEG ES for the 2 clinical indications studied—stenosis claudication and HNP radiculopathy—was quite large, suggesting that both endoscopic and IPS spinal surgery are effective in relieving symptoms due to either one of these 2 conditions. The calculated VAS-BACK ES were the higher for the IPS than for endoscopy but not statistically significant because of a large 95% CI overlap. Therefore, the authors' clinical observation that IPS implantation produces more back pain reduction than endoscopy will need to be formally studied in high quality controlled clinical trials to substantiate this conclusion. Our meta-analysis did not directly compare the clinical 2 outcomes. It instead identified the predominant clinical improvement areas—better improvement of low back pain symptoms with IPS and better radicular pain relief with directly visualized endoscopic decompression. These observations are corroborated by 2 retrospective clinical cohort studies that evaluated clinical outcomes in patients who underwent combined transforaminal

**Table 4.** Analysis of effect size, heterogeneity, and ANOVA testing of difference by surgery indication.

Indication for Surgery		Number of Studies Included in This Analysis (Multiple Study Groups Possible)	Effect Size	Lower Limit	Upper Limit	Higgins I2 Statistic of Heterogeneity	Variance	SE	N
Oswestry Disability Index	HNP radiculopathy	8	0.920	0.862	0.977	0%	0.0009	0.0295	880
	Stenosis claudication	21	0.815	0.722	0.907	0%	0.0022	0.0472	2004
						<i>P</i> = 0.076	Total <i>N</i> patients		<b>2884</b>
VAS-BACK	HNP radiculopathy	4	0.532	0.271	0.794	<1%	0.0178	0.1333	506
	Stenosis claudication	14	0.694	0.514	0.874	0%	0.0084	0.0919	2780
						<i>P</i> = 0.307	Total <i>N</i> patients		<b>3286</b>
VAS-LEG	HNP radiculopathy	8	0.868	0.769	0.966	0%	0.0025	0.0503	880
	Stenosis claudication	23	0.830	0.736	0.924	0%	0.0023	0.0480	3584
						<i>P</i> = 0.869	Total <i>N</i> patients		<b>4464</b>

Abbreviations: ANOVA, analysis of variance; HNP, herniated nucleus pulposus; VAS, visual analog scale.

**Table 5.** Analysis of effect size, heterogeneity, and ANOVA testing of difference by study type.

Study Design		Number of Studies Included in This Analysis (Multiple Study Groups Possible)	Effect Size	Lower Limit	Upper Limit	Higgins I <sup>2</sup> Statistic of Heterogeneity	Variance	SE	N
Oswestry	Prospective study	8	0.890	0.821	0.960	0%	0.0013	0.0354	1774
Disability	Randomized prospective study	11	0.843	0.729	0.957	0%	0.0034	0.0581	1374
Index	Retrospective study	32	0.884	0.846	0.922	0%	0.0004	0.0196	3314
ANOVA <i>Q</i> random effects test with separate estimates of <i>T</i> <sup>2</sup>						<i>P</i> = 0.742	Total <i>N</i>		<b>6462</b>
VAS-BACK	Prospective study	3	0.425	0.047	0.803	3%	0.0371	0.1926	284
	Randomized prospective study	11	0.806	0.653	0.959	0%	0.0061	0.0780	1542
	Retrospective study	15	0.715	0.587	0.843	0%	0.0043	0.0653	2560
ANOVA <i>Q</i> random effects test with separate estimates of <i>T</i> <sup>2</sup>						<i>P</i> = 0.112	Total <i>N</i>		<b>4386</b>
VAS-LEG	Prospective study	6	0.912	0.885	0.938	0%	0.0002	0.0136	1632
	Randomized prospective study	11	0.860	0.733	0.987	0%	0.0042	0.0650	1542
	Retrospective study	35	0.866	0.819	0.912	0%	0.0006	0.0238	4716
ANOVA <i>Q</i> random effects test with separate estimates of <i>T</i> <sup>2</sup>						<i>P</i> = 0.175	Total <i>N</i>		<b>7890</b>

Abbreviations: ANOVA, analysis of variance; VAS, visual analog scale.

endoscopic decompression with simultaneous placement of an IPS.<sup>33,158</sup> Another 2-year follow-up study performed by this team of authors on simultaneous minimally invasive IPS placement combined with an endoscopic foraminal decompression reported similar findings.<sup>159</sup> At a minimum, our meta-analysis substantiated the rationale for combining the IPS with endoscopy. However, it cannot replace a formal long-term study, which should be carried out as a prospective well-matched cohort study with a robust randomization protocol. Last but not least, implant-related problems may also need to be accounted for as their incidence is currently not known when combining these 2 minimally invasive surgeries both targeting spinal stenosis.

As discussed at the outset of this article, we were not interested in pushing endoscopic surgery in favor of IPS. We were only interested in reporting a reference data set of ODI, VAS-BACK, and VAS-LEG ES in the form of reference tables (Tables 3–5) to aid in the ongoing discussion on how to improve the durability of MISST and how to most effectively transition modern spine care to more reliable and less costly procedures by replacing some of the traditional open with endoscopic spinal surgery whose reliability could be improved by performing it in conjunction with a stabilizing procedure, such as an IPS.

We expected to find significant heterogeneity in our meta-analysis. Heterogeneity may be unfavorable in meta-analyses of randomized trials of medical or pharmacotherapeutic interventions as it would suggest significant variability in the outcomes of highly protocolized interventions. In contrast, surgical procedures may follow protocols but its outcomes are also influenced significantly by many factors and class effects (see also below). In addition, disability and pain are subjective and patient outcomes that cannot be objectively scaled

because of between-patient variability in appraisal, anchoring, and scaling. Furthermore, while previous meta-analyses were limited to prospective randomized trials,<sup>55,73–75,81,160–167</sup> we included nonrandomized prospective studies as well as retrospective analyses. Despite the evidence that well-designed observational studies do not overestimate treatment effects as compared to those obtained in randomized trials,<sup>168,169</sup> bias due to differences in the quality of studies and their designs cannot be negated. The use of random effects models in the analyses was intended to manage the observed heterogeneity.

The heterogeneity may also explain the publication bias found in our meta-analysis, a second limitation to be considered. Twenty-eight of the 48 studies included in this meta-analysis were retrospective. Many of these contributed to the spread of study-specific ES data in the 3 forest plots may have tended to cause the funnel plot to be asymmetric with many studies falling outside the funnel. Here too, the use of random effects models aimed to mitigate this bias. Heterogeneity and asymmetry may very well be inherent to surgical studies. Variation in patients' expectations; the subjectivity and relative lack of anchoring and scaling of disability ratings such as the ODI and the 2 VAS scales; differences in surgeons' skill level and preferences; variability in organizational process and procedural aspects of the surgery; and surgery being either carried out in an outpatient ambulatory surgery center or in a hospital setting; and many other factors may be responsible for the heterogeneity observed in some of the subgroups as evidenced by some of the outliers. The differences found in the ODI, VAS-BACK, and VAS-LEG ES are reflective of real-life clinical scenarios where spine care is delivered under a great variety of patient-related and system-related circumstances. The surgeon skill factor

is likely the most relevant confounder in this whole analysis and may be responsible for the wide overlap in successful clinical outcomes regardless of the type of direct or indirect lumbar decompression surgery employed.

## CONCLUSIONS

The classic indication for lumbar endoscopy has been lumbar herniation, but it has evolved to include stenosis as an indication. The indication for IPS is also lumbar spinal stenosis. Both spinal endoscopy and IPS address lumbar stenosis, albeit with different approach mechanisms, direct decompression vs indirect decompression. While the authors' hypothesis is supported by their statistical meta-analysis modeling and corroborated a limited clinical feasibility 2-year follow-up study on 33 patients,<sup>159</sup> there is a need for a long-term follow-up comparison of endoscopy with and without IPS, where potential implant-related failures and complications also will have to be taken into account when analyzing the cost-benefit equation. In spite of these limitations and considering that we did not attempt a formal comparison of endoscopy to other MISSTs or traditional open surgical decompression, our meta-analysis supports a clinically important conclusion: the addition of IPS to transforaminal lumbar endoscopic foraminal decompression may improve outcomes by reducing the residual mechanical low back pain that is often observed with this attractive outpatient surgery. The ongoing debate on the merits of endoscopic spine surgery will likely continue, for which reason the clinical merits of combining spinal endoscopy with IPS should be further studied. With this meta-analysis, we provided the statistical evidence required to have this debate in an objective manner where one wonders about the continued need for aggressive open surgeries for the indications investigated herein if the reported differences in ES gradients for clinical improvements are marginal.

## REFERENCES

1. Lewandrowski KU, Ransom NA. Five-year clinical outcomes with endoscopic transforaminal outside-in foraminoplasty techniques for symptomatic degenerative conditions of the lumbar spine. *J Spine Surg.* 2020;6(Suppl 1):S54–S65. doi:10.21037/jss.2019.07.03
2. Dowling Á, Lewandrowski K-U, da Silva FHP, Parra JAA, Portillo DM, Giménez YCP, et al. Patient selection protocols for endoscopic transforaminal, interlaminar, and translaminar decompression of lumbar spinal stenosis. *J Spine Surg.* 2020;6(Suppl 1):S120–S132. doi:10.21037/jss.2019.11.07

3. Katzell JL. Risk factors predicting less favorable outcomes in endoscopic lumbar discectomies. *J Spine Surg.* 2020;6(Suppl 1):S155–S164. doi:10.21037/jss.2019.11.04
4. Ahn J-S, Lee H-J, Choi D-J, Lee K-Y, Hwang S-J, et al. Extracranial approach of biportal endoscopic spinal surgery: a new endoscopic technique for transforaminal decompression and discectomy. *J Neurosurg Spine.* 2018;28(5):492–498. doi:10.3171/2017.8.SPINE17771
5. Ahn Y, Keum HJ, Lee S-G, Lee S-W, et al. Transforaminal endoscopic decompression for lumbar lateral recess stenosis: an advanced surgical technique and clinical outcomes. *World Neurosurg.* 2019;125:e916–e924. doi:10.1016/j.wneu.2019.01.209
6. Choi DJ, Kim JE. Efficacy of biportal endoscopic spine surgery for lumbar spinal stenosis. *Clin Orthop Surg.* 2019;11(1):82–88. doi:10.4055/cios.2019.11.1.82
7. Chung J, Kong C, Sun W, Kim D, Kim H, Jeong H, et al. Percutaneous endoscopic lumbar foraminoplasty for lumbar foraminal stenosis of elderly patients with unilateral radiculopathy: radiographic changes in magnetic resonance images. *J Neurol Surg A Cent Eur Neurosurg.* 2019;80(4):302–311. doi:10.1055/s-0038-1677052
8. Eun SS, Eum JH, Lee SH, Sabal LA, et al. Biportal endoscopic lumbar decompression for lumbar disk herniation and spinal canal stenosis: a technical note. *J Neurol Surg A Cent Eur Neurosurg.* 2017;78(4):390–396. doi:10.1055/s-0036-1592157
9. Heo DH, Lee DC, Park CK. Comparative analysis of three types of minimally invasive decompressive surgery for lumbar central stenosis: biportal endoscopy, uniportal endoscopy, and microsurgery. *Neurosurg Focus.* 2019;46(5):2019.2.FOCUS197. doi:10.3171/2019.2.FOCUS197
10. Imajo Y, Taguchi T, Neo M, et al. Complications of spinal surgery for elderly patients with lumbar spinal stenosis in a super-aging country: an analysis of 8033 patients. *J Orthop Sci.* 2017;22(1):10–15. doi:10.1016/j.jos.2016.08.014
11. An K-C, Kong G-M, Park D-H, Baik J-M, Youn J-H, Lee W-S, et al. Comparison of posterior lumbar interbody fusion and posterolateral lumbar fusion in monosegmental vacuum phenomenon within an intervertebral disc. *Asian Spine J.* 2016;10(1):93–98. doi:10.4184/asj.2016.10.1.93
12. Liao J-C, Lu M-L, Niu C-C, Chen W-J, Chen L-H, et al. Surgical outcomes of degenerative lumbar spondylolisthesis with anterior vacuum disc: can the intervertebral cage overcome intradiscal vacuum phenomenon and enhance posterolateral fusion? *J Orthop Sci.* 2014;19(6):851–859. doi:10.1007/s00776-014-0618-z
13. Lin T-Y, Liao J-C, Tsai T-T, et al. The effects of anterior vacuum disc on surgical outcomes of degenerative versus spondylolytic spondylolisthesis: at a minimum two-year follow-up. *BMC Musculoskelet Disord.* 2014;15:329. doi:10.1186/1471-2474-15-329
14. Murata K, Akeda K, Takegami N, Cheng K, Masuda K, Sudo A, et al. Morphology of intervertebral disc ruptures evaluated by vacuum phenomenon using multi-detector computed tomography: association with lumbar disc degeneration and canal stenosis. *BMC Musculoskelet Disord.* 2018;19(1):164. doi:10.1186/s12891-018-2086-7
15. Söffler C, Karpenstein H, Kramer M. The intervertebral vacuum phenomenon as a computed-tomographic finding in the dog and its significance as an indicator for surgical treatment of vertebral disc herniations. *Tierarztl Prax Ausg K Kleintiere Heimtiere.* 2014;42(2):88–93. doi:10.1055/s-0038-1623746



16. Schweitzer ME, el-Noueam KI. Vacuum disc: frequency of high signal intensity on T2-weighted MR images. *Skeletal Radiol.* 1998;27(2):83–86. doi:10.1007/s002560050342
17. Lewandrowski K-U, León JFR, Yeung A. Use of “inside-out” technique for direct visualization of a vacuum vertically unstable intervertebral disc during routine lumbar endoscopic transforaminal decompression—a correlative study of clinical outcomes and the prognostic value of lumbar radiographs. *Int J Spine Surg.* 2019;13(5):399–414. doi:10.14444/6055
18. Sebro R, O’Brien L, Torriani M, Bredella MA, et al. Assessment of trunk muscle density using CT and its association with degenerative disc and facet joint disease of the lumbar spine. *Skeletal Radiol.* 2016;45(9):1221–1226. doi:10.1007/s00256-016-2405-8
19. Sun D, Liu P, Cheng J, Ma Z, Liu J, Qin T, et al. Correlation between intervertebral disc degeneration, paraspinal muscle atrophy, and lumbar facet joints degeneration in patients with lumbar disc herniation. *BMC Musculoskelet Disord.* 2017;18(1):167. doi:10.1186/s12891-017-1522-4
20. Yoshiiwa T, Miyazaki M, Notani N, Ishihara T, Kawano M, Tsumura H, et al. Analysis of the relationship between ligamentum flavum thickening and lumbar segmental instability, disc degeneration, and facet joint osteoarthritis in lumbar spinal stenosis. *Asian Spine J.* 2016;10(6):1132–1140. doi:10.4184/asj.2016.10.6.1132
21. Yeung A, Lewandrowski KU. Five-year clinical outcomes with endoscopic transforaminal foraminoplasty for symptomatic degenerative conditions of the lumbar spine: a comparative study of *inside-out* versus *outside-in* techniques. *J Spine Surg.* 2020;6(Suppl 1):S66–S83. doi:10.21037/jss.2019.06.08
22. Lewandrowski KU. Incidence, management, and cost of complications after transforaminal endoscopic decompression surgery for lumbar foraminal and lateral recess stenosis: a value proposition for outpatient ambulatory surgery. *Int J Spine Surg.* 2019;13(1):53–67. doi:10.14444/6008
23. Lewandrowski KU. Readmissions after outpatient transforaminal decompression for lumbar foraminal and lateral recess stenosis. *Int J Spine Surg.* 2018;12(3):342–351. doi:10.14444/5040
24. Yeung A, Roberts A, Zhu L, Qi L, Zhang J, Lewandrowski K-U, et al. Treatment of soft tissue and bony spinal stenosis by a visualized endoscopic transforaminal technique under local anesthesia. *Neurospine.* 2019;16(1):52–62. doi:10.14245/ns.1938038.019
25. Ahn Y, Lee U, Kim W-K, Keum HJ, et al. Five-year outcomes and predictive factors of transforaminal full-endoscopic lumbar discectomy. *Medicine (Baltimore).* 2018;97(48):e13454. doi:10.1097/MD.00000000000013454
26. Fischgrund JS, Rhyne A, Franke J, et al. Intraosseous basivertebral nerve ablation for the treatment of chronic low back pain: 2-year results from a prospective randomized double-blind sham-controlled multicenter study. *Int J Spine Surg.* 2019;13(2):110–119. doi:10.14444/6015
27. Katzell JL. Risk factors predicting less favorable outcomes in endoscopic lumbar discectomies. *J Spine Surg.* 2020;6(Suppl 1):S155–S164. doi:10.21037/jss.2019.11.04
28. Knight M, Goswami A. Lumbar percutaneous KTP532 wavelength laser disc decompression and disc ablation in the management of discogenic pain. *J Clin Laser Med Surg.* 2002;20(1):9–13. doi:10.1089/104454702753474940
29. Knight MT, Ellison DR, Goswami A, Hillier VF, et al. Review of safety in endoscopic laser foraminoplasty for the management of back pain. *J Clin Laser Med Surg.* 2001;19(3):147–157. doi:10.1089/10445470152927982
30. Lee SH, Kang HS. Percutaneous endoscopic laser annuloplasty for discogenic low back pain. *World Neurosurg.* 2010;73(3):198–206. doi:10.1016/j.surneu.2009.01.023
31. Lewandrowski K-U, Ransom NA, Ramírez León JF, Yeung A, et al. The concept for a standalone lordotic endoscopic wedge lumbar interbody fusion: the LEW-LIF. *Neurospine.* 2019;16(1):82–95. doi:10.14245/ns.1938046.023
32. Ramírez León JF, Ardila AS, Rugeles Ortíz JG, et al. Standalone lordotic endoscopic wedge lumbar interbody fusion (LEW-LIF) with a threaded cylindrical peek cage: report of two cases. *J Spine Surg.* 2020;6(Suppl 1):S275–S284. doi:10.21037/jss.2019.06.09
33. Liu G, Zhao JN, Dezawa A. Endoscopic decompression combined with interspinous process implant fusion for lumbar spinal stenosis. *Chin J Traumatol.* 2008;11(6):364–367. doi:10.1016/s1008-1275(08)60073-5
34. Bini W, Miller LE, Block JE. Minimally invasive treatment of moderate lumbar spinal stenosis with the superior interspinous spacer. *Open Orthop J.* 2011;5:361–367. doi:10.2174/1874325001105010361
35. Loguidice V, Bini W, Shabat S, Miller LE, Block JE, et al. Rationale, design and clinical performance of the superior® interspinous spacer: a minimally invasive implant for treatment of lumbar spinal stenosis. *Expert Rev Med Devices.* 2011;8(4):419–426. doi:10.1586/erd.11.24
36. Merkow J, Varhabhatla N, Manchikanti L, Kaye AD, Urman RD, Yong RJ, et al. Minimally invasive lumbar decompression and interspinous process device for the management of symptomatic lumbar spinal stenosis: a literature review. *Curr Pain Headache Rep.* 2020;24(4):13. doi:10.1007/s11916-020-0845-2
37. Shabat S, Miller LE, Block JE, Gepstein R, et al. Minimally invasive treatment of lumbar spinal stenosis with a novel interspinous spacer. *Clin Interv Aging.* 2011;6:227–233. doi:10.2147/CIA.S23656
38. Arroategui I. Coflex interspinous spacer. Use in degenerative lumbar disc herniation. *Acta Ortop Mex.* 2010;24(3):187–190.
39. Chen Y-H, Xu D, Xu H-Z, Chi Y-L, Wang X-Y, Huang Q-S, et al. Coflex interspinous dynamic internal fixation for the treatment of degenerative lumbar spinal stenosis. *Zhongguo Gu Shang.* 2009;22(12):902–905.
40. Chiu JC. Interspinous process decompression (IPD) system (X-STOP) for the treatment of lumbar spinal stenosis. *Surg Technol Int.* 2006;15:265–275.
41. Hartjen CA, Resnick DK, Hsu KY, Zucherman JF, Hsu EH, Skidmore GA, et al. Two-year evaluation of the X-STOP interspinous spacer in different primary patient populations with neurogenic intermittent claudication because of lumbar spinal stenosis. *Clin Spine Surg.* 2016;29(7):305–311. doi:10.1097/BSD.0b013e31827b671f
42. Masala S, Marcia S, Taglieri A, et al. Degenerative lumbar spinal stenosis treatment with Aperius PerCLID system and Falena(R) interspinous spacers: 1-year follow-up of clinical outcome and quality of life. *Interv Neuroradiol.* 2016;22(2):217–226. doi:10.1177/1591019915622163
43. Menchetti PPM, Postacchini F, Bini W, Canero G, et al. Percutaneous surgical treatment in lumbar spinal stenosis with Aperius-PerCLID: indications, surgical technique and results. *Acta Neurochir Suppl.* 2011;108:183–186. doi:10.1007/978-3-211-99370-5\_27
44. Nicholson JA, Scott CEH, Duckworth AD, Burke JG, Gibson JNA, et al. Survival analysis of the wallis interspinous

- spacer used as an augment to lumbar decompression. *Br J Neurosurg.* 2017;31(6):688–694. doi:10.1080/02688697.2017.1351522
45. Laurysen C, Jackson RJ, Baron JM, et al. Stand-alone interspinous spacer versus decompressive laminectomy for treatment of lumbar spinal stenosis. *Expert Rev Med Devices.* 2015;12(6):763–769. doi:10.1586/17434440.2015.1100071
46. Miller LE, Block JE. Interspinous spacer implant in patients with lumbar spinal stenosis: preliminary results of a multicenter, randomized, controlled trial. *Pain Res Treat.* 2012;2012:823509. doi:10.1155/2012/823509
47. Nunley PD, Patel VV, Orndorff DG, Block J, Lavelle WF, Geisler F. Four-year results of a randomized controlled trial for treatment of moderate lumbar spinal stenosis with InterSpinous spacer. *The Spine Journal.* 2017;17(10):S265. doi:10.1016/j.spinee.2017.08.201
48. Nunley PD, Patel VV, Orndorff DG, Lavelle WF, Block JE, Geisler FH. Five-year durability of stand-alone interspinous process decompression for lumbar spinal stenosis. *Clin Interv Aging.* 2017;12:1409–1417. doi:10.2147/CIA.S143503
49. Nunley PD, Patel VV, Orndorff DG, Lavelle WF, Block JE, Geisler FH. Interspinous process decompression improves quality of life in patients with lumbar spinal stenosis. *Minim Invasive Surg.* 2018;2018:1035954. doi:10.1155/2018/1035954
50. Nunley PD, Shamie AN, Blumenthal SL, Orndorff D, Block JE, Geisler FH, et al. Interspinous process decompression: expanding treatment options for lumbar spinal stenosis. *Biomed Res Int.* 2016;2016:3267307. doi:10.1155/2016/3267307
51. Parker SL, Anderson LH, Nelson T, Patel VV, et al. Cost-effectiveness of three treatment strategies for lumbar spinal stenosis: conservative care, laminectomy, and the superior interspinous spacer. *Int J Spine Surg.* 2015;9:28. doi:10.14444/2028
52. Patel VV, Whang PG, Haley TR, et al. Superior interspinous process spacer for intermittent neurogenic claudication secondary to moderate lumbar spinal stenosis: two-year results from a randomized controlled FDA-IDE pivotal trial. *Spine (Phila Pa 1976).* 2015;40(5):275–282. doi:10.1097/BRS.0000000000000735
53. Patel VV, Whang PG, Haley TR, et al. Two-year clinical outcomes of a multicenter randomized controlled trial comparing two interspinous spacers for treatment of moderate lumbar spinal stenosis. *BMC Musculoskelet Disord.* 2014;15:221. doi:10.1186/1471-2474-15-221
54. Whang PG, Patel VV, Bradley WD, Block JE, et al. Midterm outcomes of a prospective multicenter randomized controlled trial comparing the clinical efficacy of interspinous spacers as a treatment for moderate lumbar spinal stenosis. *The Spine Journal.* 2013;13(9):S136–S137. doi:10.1016/j.spinee.2013.07.352
55. Zhao H, Duan L-J, Gao Y-S, et al. Comparison of two FDA-approved interspinous spacers for treatment of lumbar spinal stenosis: superior versus X-STOP-a meta-analysis from five randomized controlled trial studies. *J Orthop Surg Res.* 2018;13(1):42. doi:10.1186/s13018-018-0742-0
56. Cairns K, Deer T, Sayed D, van Noort K, Liang K, et al. Cost-effectiveness and safety of interspinous process decompression (superior). *Pain Med.* 2019;20(Suppl 2):S2–S8. doi:10.1093/pm/pnz245
57. Yaghoubi M, Moradi-Lakeh M, Moradi-Joo M, Rahimi-Movaghar V, Zamani N, Naghibzadeh-Tahami A, et al. The cost effectiveness of dynamic and static interspinous spacer for lumbar spinal stenosis compared with laminectomy. *Med J Islam Repub Iran.* 2016;30:339.
58. Neely WF, Fichtel F, Del Monaco DC, Block JE, et al. Treatment of symptomatic lumbar disc degeneration with the VariLift-L interbody fusion system: retrospective review of 470 cases. *Int J Spine Surg.* 2016;10:15. doi:10.14444/3015
59. Kepler CK, Rihn JA, Radcliff KE, et al. Restoration of lordosis and disk height after single-level transforaminal lumbar interbody fusion. *Orthop Surg.* 2012;4(1):15–20. doi:10.1111/j.1757-7861.2011.00165.x
60. Liu E, Yin Q, Guo D. Long-term follow-up study on expandable Cage in treatment of degenerative lumbar disease. *Zhongguo Xiu Fu Chong Jian Wai Ke Za Zhi.* 2014;28(5):540–543.
61. Ahn Y, Kim W-K, Son S, Lee S-G, Jeong YM, Im T, et al. Radiographic assessment on magnetic resonance imaging after percutaneous endoscopic lumbar foraminotomy. *Neurol Med Chir (Tokyo).* 2017;57(12):649–657. doi:10.2176/nmc.2016-0249
62. Kim CW, Doerr TM, Luna IY, et al. Minimally invasive transforaminal lumbar interbody fusion using expandable technology: a clinical and radiographic analysis of 50 patients. *World Neurosurg.* 2016;90:228–235. doi:10.1016/j.wneu.2016.02.075
63. Hawasli AH, Khalifeh JM, Chatrath A, Yarbrough CK, Ray WZ, et al. Minimally invasive transforaminal lumbar interbody fusion with expandable versus static interbody devices: radiographic assessment of sagittal segmental and pelvic parameters. *Neurosurg Focus.* 2017;43(2):E10. doi:10.3171/2017.5.FOCUS17197
64. Kale A, Oz II, Onk A, Kalaycı M, Büyükuysal Ç. Unilaterally posterior lumbar interbody fusion with double expandable peek cages without pedicle screw support for lumbar disc herniation. *Neurol Neurochir Pol.* 2017;51(1):53–59. doi:10.1016/j.pjnns.2016.11.001
65. Yee TJ, Joseph JR, Terman SW, Park P. Expandable vs static cages in transforaminal lumbar interbody fusion: radiographic comparison of segmental and lumbar sagittal angles. *Neurosurgery.* 2017;81(1):69–74. doi:10.1093/neuros/nyw177
66. Parker SL, Mendenhall SK, Godil SS, et al. Incidence of low back pain after lumbar discectomy for herniated disc and its effect on patient-reported outcomes. *Clin Orthop Relat Res.* 2015;473(6):1988–1999. doi:10.1007/s11999-015-4193-1
67. Wang H, Zhou Y, Li C, Liu J, Xiang L, et al. Risk factors for failure of single-level percutaneous endoscopic lumbar discectomy. *J Neurosurg Spine.* 2015;23(3):320–325. doi:10.3171/2014.10.SPINE1442
68. Kong DS, Kim ES, Eoh W. One-year outcome evaluation after interspinous implantation for degenerative spinal stenosis with segmental instability. *J Korean Med Sci.* 2007;22(2):330–335. doi:10.3346/jkms.2007.22.2.330
69. Cabraja M, Abbushi A, Woiciechowsky C, Kroppenstedt S, et al. The short- and mid-term effect of dynamic interspinous distraction in the treatment of recurrent lumbar facet joint pain. *Eur Spine J.* 2009;18(11):1686–1694. doi:10.1007/s00586-009-1149-8
70. Errico TJ, Kamerlink JR, Quirno M, Samani J, Chomiak RJ. Survivorship of coflex interlaminar-interspinous implant. *SAS J.* 2009;3(2):59–67. doi:10.1016/SASJ-2008-0027-RR
71. Buric J, Pulidori M. Long-term reduction in pain and disability after surgery with the interspinous device for intervertebral assisted motion (DIAM) spinal stabilization system in patients with low back pain: 4-year follow-up from a longitudinal prospective case series. *Eur Spine J.* 2011;20(8):1304–1311. doi:10.1007/s00586-011-1697-6
72. Rouben D, Casnellie M, Ferguson M. Long-term durability of minimal invasive posterior transforaminal lumbar interbody

fusion. *J Spinal Disord Tech.* 2011;24(5):288–296. doi:10.1097/BSD.0b013e3181f9a60a

73. Moojen WA, Arts MP, Bartels RHMA, Jacobs WCH, Peul WC, et al. Effectiveness of interspinous implant surgery in patients with intermittent neurogenic claudication: a systematic review and meta-analysis. *Eur Spine J.* 2011;20(10):1596–1606. doi:10.1007/s00586-011-1873-8

74. Machado GC, Ferreira PH, Harris IA, et al. Effectiveness of surgery for lumbar spinal stenosis: a systematic review and meta-analysis. *PLoS ONE.* 2015;10(3):e0122800. doi:10.1371/journal.pone.0122800

75. Phan K, Rao PJ, Ball JR, Mobbs RJ. Interspinous process spacers versus traditional decompression for lumbar spinal stenosis: systematic review and meta-analysis. *J Spine Surg.* 2016;2(1):31–40. doi:10.21037/jss.2016.01.07

76. Ravindra VM, Ghogawala Z. Is there still a role for interspinous spacers in the management of neurogenic claudication? *Neurosurgery Clinics of North America.* 2017;28(3):321–330. doi:10.1016/j.nec.2017.02.002

77. Fairbank J. Use of Oswestry disability index (ODI). *Spine (Phila Pa 1976).* 1995;20(13):1535–1537. doi:10.1097/00007632-199507000-00020

78. Fairbank JCT, Pynsent PB. The Oswestry disability index. *Spine (Phila Pa 1976).* 2000;25(22):2940–2952. doi:10.1097/00007632-200011150-00017

79. van Hooff ML, Spruit M, Fairbank JCT, van Limbeek J, Jacobs WCH, et al. The Oswestry disability index (version 2.1a): validation of a Dutch language version. *Spine (Phila Pa 1976).* 2015;40(2):E83–90. doi:10.1097/BRS.0000000000000683

80. Reed CC, Wolf WA, Cotton CC, Dellon ES, et al. A visual analogue scale and a Likert scale are simple and responsive tools for assessing dysphagia in eosinophilic oesophagitis. *Aliment Pharmacol Ther.* 2017;45(11):1443–1448. doi:10.1111/apt.14061

81. Zhang B, Liu S, Liu J, et al. Transforaminal endoscopic discectomy versus conventional microdiscectomy for lumbar disc herniation: a systematic review and meta-analysis. *J Orthop Surg Res.* 2018;13(1):169. doi:10.1186/s13018-018-0868-0

82. Hutton B, Salanti G, Caldwell DM, et al. The PRISMA extension statement for reporting of systematic reviews incorporating network meta-analyses of health care interventions: checklist and explanations. *Ann Intern Med.* 2015;162(11):777–784. doi:10.7326/M14-2385

83. Liberati A, Altman DG, Tetzlaff J, et al. The PRISMA statement for reporting systematic reviews and meta-analyses of studies that evaluate healthcare interventions: explanation and elaboration. *BMJ.* 2009;339:bmj.b2700. doi:10.1136/bmj.b2700

84. Liu H, Zhou X, Yu G, Sun X, et al. The effects of the PRISMA statement to improve the conduct and reporting of systematic reviews and meta-analyses of nursing interventions for patients with heart failure. *Int J Nurs Pract.* 2019;25(3):e12729. doi:10.1111/ijn.12729

85. McGrath LB, White-Dzuro GA, Hofstetter CP. Comparison of clinical outcomes following minimally invasive or lumbar endoscopic unilateral laminotomy for bilateral decompression. *J Neurosurg Spine.* 2019;30(4):491–499. doi:10.3171/2018.9.SPINE18689

86. McInnes MDF, Moher D, Thombs BD, et al. Preferred reporting items for a systematic review and meta-analysis of diagnostic test accuracy studies: the PRISMA-DTA statement. *JAMA.* 2018;319(4):388–396. doi:10.1001/jama.2017.19163

87. Page MJ, Moher D. Evaluations of the uptake and impact of the preferred reporting items for systematic reviews and

meta-analyses (PRISMA) statement and extensions: a scoping review. *Syst Rev.* 2017;6(1):263. doi:10.1186/s13643-017-0663-8

88. Poveda-Montoyo I, Belinchón-Romero I, Romero-Pérez D, Ramos-Rincón JM, et al. Topics and PRISMA checklist compliance for meta-analyses in dermatology: journal case study. *Acta Dermatovenerol Croat.* 2019;27(4):275–277.

89. Moher D, Shamseer L, Clarke M, et al. Preferred reporting items for systematic review and meta-analysis protocols (PRISMA-P) 2015 statement. *Syst Rev.* 2015;4:1. doi:10.1186/2046-4053-4-1

90. Hara N, Matsudaira K, Masuda K, et al. Psychometric assessment of the Japanese version of the Zurich claudication questionnaire (ZCQ): reliability and validity. *PLoS One.* 2016;11(7):e0160183. doi:10.1371/journal.pone.0160183

91. Hidalgo Ovejero AM, Menéndez García M, Bermejo Fraile B, García Mata S, Forcén Alonso T, Mateo Sebastián P, et al. Cross-cultural adaptation of the Zurich claudication questionnaire. Validation study of the Spanish version. *An Sist Sanit Navar.* 2015;38(1):41–52. doi:10.23938/ASSN.0052

92. Kim H-J, Lee Y-K, Kim DO, Chang B-S, Lee C-K, Yeom JS, et al. Validation and cross-cultural adaptation of the Korean version of the Zurich claudication questionnaire in patients with lumbar spinal stenosis. *Spine.* 2018;43(2):E105–E110. doi:10.1097/BRS.0000000000002241

93. Saltychev M, Virolainen P. Validation and cross-cultural adaptation of the Korean version of the Zurich claudication questionnaire in patients with lumbar spinal stenosis. *Spine (Phila Pa 1976).* 2018.

94. Cohen J. *Statistical Power Analysis for the Behavioral Sciences.* Hillsdale, NJ: Publisher unknown; 1988.

95. COHEN J. The statistical power of abnormal-social psychological research: a review. *J Abnorm Soc Psychol.* 1962;65:145–153. doi:10.1037/h0045186

96. Azimi P, Yazdaniyan T, Benzel EC. Determination of minimally clinically important differences for JOABPEQ measure after discectomy in patients with lumbar disc herniation. *J Spine Surg.* 2018;4(1):102–108. doi:10.21037/jss.2018.03.11

97. Cook CE. Clinimetrics corner: the minimal clinically important change score (MCID): a necessary pretense. *J Man Manip Ther.* 2008;16(4):E82–3. doi:10.1179/jmt.2008.16.4.82E

98. Copay AG, Eyberg B, Chung AS, Zurcher KS, Chutkan N, Spangehl MJ, et al. Minimum clinically important difference: current trends in the orthopaedic literature, part ii: lower extremity: a systematic review. *JBJS Rev.* 2018;6(9):e2. doi:10.2106/JBJS.RVW.17.00160

99. Held U, Burgstaller JM, Wertli MM, et al. Prognostic function to estimate the probability of meaningful clinical improvement after surgery - Results of a prospective multicenter observational cohort study on patients with lumbar spinal stenosis. *PLoS One.* 2018;13(11):e0207126. doi:10.1371/journal.pone.0207126

100. Jaeschke R, Singer J, Guyatt GH. Measurement of health status. Ascertain the minimal clinically important difference. *Control Clin Trials.* 1989;10(4):407–415. doi:10.1016/0197-2456(89)90005-6

101. Lauridsen HH, Hartvigsen J, Manniche C, Korsholm L, Grunnet-Nilsson N, et al. Responsiveness and minimal clinically important difference for pain and disability instruments in low back pain patients. *BMC Musculoskelet Disord.* 2006;7:82. doi:10.1186/1471-2474-7-82

102. Ahn Y, Lee SG, Son S, Keum HJ, et al. Transforaminal endoscopic lumbar discectomy versus open lumbar

- microdiscectomy: a comparative cohort study with a 5-year follow-up. *Pain Physician*. 2019;22(3):295–304.
103. Bai Y, Xu L, Xi J, Mu X, et al. Diagnosis and treatment of lumbar disc herniation by discography and percutaneous transforaminal endoscopic surgery. *Zhonghua Yi Xue Za Zhi*. 2012;92(47):3350–3353.
104. Choi G, Lee S-H, Bhanot A, Raiturker PP, Chae YS, et al. Percutaneous endoscopic discectomy for extraforaminal lumbar disc herniations: extraforaminal targeted fragmentectomy technique using working channel endoscope. *Spine (Phila Pa 1976)*. 2007;32(2):E93-9. doi:10.1097/01.brs.0000252093.31632.54
105. Choi G, Modi HN, Prada N, et al. Clinical results of XMR-assisted percutaneous transforaminal endoscopic lumbar discectomy. *J Orthop Surg Res*. 2013;8:14. doi:10.1186/1749-799X-8-14
106. Choi KC, Kim JS, Park CK. Percutaneous endoscopic lumbar discectomy as an alternative to open lumbar microdiscectomy for large lumbar disc herniation. *Pain Physician*. 2016;19(2):E291-300. doi:10.36076/ppj.2016.19.E291
107. Choi KC, Park CK. Percutaneous endoscopic lumbar discectomy for L5-S1 disc herniation: consideration of the relation between the iliac crest and L5-S1 disc. *Pain Physician*. 2016;19(2):E301-8.
108. Dey PC, Nanda SN. Functional outcome after endoscopic lumbar discectomy by standau's technique: a prospective study of 614 patients. *Asian Spine J*. 2019;13(5):786–792. doi:10.31616/asj.2018.0320
109. Eun SS, Lee SH, Erken HY. Transforaminal percutaneous endoscopic lumbar discectomy for downmigrated disk herniations: lever-up, rotate, and tilt technique. *J Neurol Surg A Cent Eur Neurosurg*. 2018;79(2):163–168. doi:10.1055/s-0037-1608837
110. Gibson JNA, Subramanian AS, Scott CEH. A randomised controlled trial of transforaminal endoscopic discectomy vs microdiscectomy. *Eur Spine J*. 2017;26(3):847–856. doi:10.1007/s00586-016-4885-6
111. Kim HS, Adsul N, Kapoor A, et al. A mobile outside-in technique of transforaminal lumbar endoscopy for lumbar disc herniations. *J Vis Exp*. 2018;(138). doi:10.3791/57999
112. Kim JE, Choi DJ. Bi-portal arthroscopic spinal surgery (BASS) with 30° arthroscopy for far lateral approach of L5-S1 - Technical note. *J Orthop*. 2018;15(2):354–358. doi:10.1016/j.jor.2018.01.034
113. Komp M, Hahn P, Ozdemir S, et al. Operation of lumbar zygoapophyseal joint cysts using a full-endoscopic interlaminar and transforaminal approach: prospective 2-year results of 74 patients. *Surg Innov*. 2014;21(6):605–614. doi:10.1177/1553350614525668
114. Li H, Jiang C, Mu X, Lan W, Zhou Y, Li C, et al. Comparison of MED and PELD in the treatment of adolescent lumbar disc herniation: a 5-year retrospective follow-up. *World Neurosurg*. 2018;112:e255–e260. doi:10.1016/j.wneu.2018.01.030
115. Liu C, Chu L, Yong H-C, Chen L, Deng Z-L, et al. Percutaneous endoscopic lumbar discectomy for highly migrated lumbar disc herniation. *Pain Physician*. 2017;20(1):E75–E84. doi:10.36076/ppj.2017.1.E75
116. Pan F, Shen B, Chy SK, et al. Transforaminal endoscopic system technique for discogenic low back pain: a prospective cohort study. *Int J Surg*. 2016;35:134–138. doi:10.1016/j.ijss.2016.09.091
117. Soliman HM. Irrigation endoscopic discectomy: a novel percutaneous approach for lumbar disc prolapse. *Eur Spine J*. 2013;22(5):1037–1044. doi:10.1007/s00586-013-2701-0
118. Song H, Hu W, Liu Z, Hao Y, Zhang X, et al. Percutaneous endoscopic interlaminar discectomy of L5-S1 disc herniation: a comparison between intermittent endoscopy technique and full endoscopy technique. *J Orthop Surg Res*. 2017;12(1):162. doi:10.1186/s13018-017-0662-4
119. Teli M, Lovi A, Brayda-Bruno M, et al. Higher risk of dural tears and recurrent herniation with lumbar micro-endoscopic discectomy. *Eur Spine J*. 2010;19(3):443–450. doi:10.1007/s00586-010-1290-4
120. Tu Z, Li YW, Wang B, et al. Clinical outcome of full-endoscopic interlaminar discectomy for single-level lumbar disc herniation: a minimum of 5-year follow-up. *Pain Physician*. 2017;20(3):E425–E430. doi:10.36076/ppj.2017.E430
121. Tu Z, Wang B, Li L, et al. Early experience of full-endoscopic interlaminar discectomy for adolescent lumbar disc herniation with sciatic scoliosis. *Pain Physician*. 2018;21(1):E63–E70. doi:10.36076/ppj.2018.1.E63
122. Zhang W Met al. Transforaminal endoscopic discectomy for treatment of central disc herniation: surgical techniques and clinical outcome. *Pain Phys*. 2018;1(21;1):E113–E123. doi:10.36076/ppj.2018.2.E113. <https://www.painphysicianjournal.com/current/past?journal=109>
123. Wang Y-P, Zhang W, An J-L, Zhang J, Bai J-Y, Sun Y-P, et al. Evaluation of transforaminal endoscopic discectomy in treatment of obese patients with lumbar disc herniation. *Med Sci Monit*. 2016;22:2513–2519. doi:10.12659/msm.899510
124. Xu B, Xu H, Ma X, et al. Bilateral decompression and intervertebral fusion via unilateral fenestration for complex lumbar spinal stenosis with a mobile microendoscopic technique. *Medicine*. 2018;97(4):e9715. doi:10.1097/MD.00000000000009715
125. Youn MS, Shin JK, Goh TS, Son SM, Lee JS, et al. Endoscopic posterior decompression under local anesthesia for degenerative lumbar spinal stenosis. *J Neurosurg Spine*. 2018;29(6):661–666. doi:10.3171/2018.5.SPINE171337
126. Zhang B, Kong Q, Yang J, Feng P, Ma J, Liu J, et al. Short-term effectiveness of percutaneous endoscopic transforaminal bilateral decompression for severe central lumbar spinal stenosis. *Zhongguo Xiu Fu Chong Jian Wai Ke Za Zhi*. 2019;33(11):1399–1405. doi:10.7507/1002-1892.201904131
127. Lewandrowski K-U, de Carvalho PST, Calderaro AL, et al. Outcomes with transforaminal endoscopic versus percutaneous laser decompression for contained lumbar herniated disc: a survival analysis of treatment benefit. *J Spine Surg*. 2020;6(Suppl 1):S84–S99. doi:10.21037/jss.2019.09.13
128. Abdel Ghany W, Amer A, Saeed K, et al. Evaluation of interspinous spacer outcomes in degenerative lumbar canal stenosis: clinical study. *World Neurosurg*. 2016;95(556–64):556–564. doi:10.1016/j.wneu.2016.07.095
129. Haley TR, Miller LE, Block JE. Mid-term outcomes of a prospective randomized controlled trial of interspinous spacer treatment for moderate lumbar spinal stenosis. *PM&R*. 2013;5:S287–S287. doi:10.1016/j.pmrj.2013.08.510
130. Korovessis P, Syrimpeis V, Tsekouras V, Vardakastanis K, Fennema P, et al. PEEK versus silicon interspinous spacer for reduction of supradjacent segment degeneration following decompression and short-segment instrumentation for degenerative lumbar spinal stenosis. *Adv Orthop*. 2018;2018:1623647. doi:10.1155/2018/1623647
131. Gu H, Chang Y, Zeng S, et al. Wallis interspinous spacer for treatment of primary lumbar disc herniation: three-year results of a randomized controlled trial. *World Neurosurg*. 2018;120:e1331–e1336. doi:10.1016/j.wneu.2018.09.086

132. Lønne G, Johnsen LG, Aas E, et al. Comparing cost-effectiveness of X-stop with minimally invasive decompression in lumbar spinal stenosis. *Spine (Phila Pa 1976)*. 2015;40(8):514–520. doi:10.1097/BRS.0000000000000798
133. Masala S, Fiori R, Bartolucci DA, et al. Percutaneous decompression of lumbar spinal stenosis with a new interspinous device. *Cardiovasc Intervent Radiol*. 2012;35(2):368–374. doi:10.1007/s00270-011-0167-1
134. Nunley PD, Patel VV, Orndorff DG, Lavelle WF, Block JE, Geisler FH. Superior interspinous spacer treatment of moderate spinal stenosis: 4-year results. *World Neurosurg*. 2017;104:279–283. doi:10.1016/j.wneu.2017.04.163
135. Postacchini R, Ferrari E, Cinotti G, Menchetti PPM, Postacchini F, et al. Aperius interspinous implant versus open surgical decompression in lumbar spinal stenosis. *Spine J*. 2011;11(10):933–939. doi:10.1016/j.spinee.2011.08.419
136. Richter A, Schütz C, Hauck M, Halm H, et al. Does an interspinous device (Coflex) improve the outcome of decompressive surgery in lumbar spinal stenosis? One-year follow up of a prospective case control study of 60 patients. *Eur Spine J*. 2010;19(2):283–289. doi:10.1007/s00586-009-1229-9
137. Sénégas J. Mechanical supplementation by non-rigid fixation in degenerative intervertebral lumbar segments: the wallis system. *Eur Spine J*. 2002;11 Suppl 2:S164–9. doi:10.1007/s00586-002-0423-9
138. Surace MF, Fagetti A, Fozzato S, Cherubino P, et al. Lumbar spinal stenosis treatment with aperius perclid interspinous system. *Eur Spine J*. 2012;21 Suppl 1:S69–74. doi:10.1007/s00586-012-2222-2
139. Strömqvist BH, Berg S, Gerdhem P, et al. X-stop versus decompressive surgery for lumbar neurogenic intermittent claudication: randomized controlled trial with 2-year follow-up. *Spine (Phila Pa 1976)*. 2013;38(17):1436–1442. doi:10.1097/BRS.0b013e31828ba413
140. Tekmyster G, Sayed D, Cairns KD, Raso LJ, Kim C, Block JE, et al. Interspinous process decompression with the superior® spacer for lumbar spinal stenosis: real-world experience from a device registry. *Med Devices (Auckl)*. 2019;12:423–427. doi:10.2147/MDER.S220431
141. Puzzilli F, Gazzeri R, Galarza M, et al. Interspinous spacer decompression (X-STOP) for lumbar spinal stenosis and degenerative disk disease: a multicenter study with a minimum 3-year follow-up. *Clin Neurol Neurosurg*. 2014;124:166–174. doi:10.1016/j.clineuro.2014.07.004
142. Sobottke R, Schlüter-Brust K, Kaulhausen T, et al. Interspinous implants (X Stop, Wallis, Diam) for the treatment of LSS: is there a correlation between radiological parameters and clinical outcome? *Eur Spine J*. 2009;18(10):1494–1503. doi:10.1007/s00586-009-1081-y
143. Yeung A, Lewandrowski KU. Early and staged endoscopic management of common pain generators in the spine. *J Spine Surg*. 2020;6(Suppl 1):S1–S5. doi:10.21037/jss.2019.09.03
144. Kantelhardt SR, Török E, Gempt J, et al. Safety and efficacy of a new percutaneously implantable interspinous process device. *Acta Neurochir (Wien)*. 2010;152(11):1961–1967. doi:10.1007/s00701-010-0740-4
145. Park S-C, Yoon SH, Hong Y-P, Kim K-J, Chung S-K, Kim H-J, et al. Minimum 2-year follow-up result of degenerative spinal stenosis treated with interspinous u (coflex). *J Korean Neurosurg Soc*. 2009;46(4):292–299. doi:10.3340/jkns.2009.46.4.292
146. Patel VV, Nunley PD, Whang PG, et al. Superior® interspinous spacer for treatment of moderate degenerative lumbar spinal stenosis: durable three-year results of a randomized controlled trial. *J Pain Res*. 2015;8:657–662. doi:10.2147/JPR.S92633
147. Richter A, Halm HFH, Hauck M, Quante M, et al. Two-year follow-up after decompressive surgery with and without implantation of an interspinous device for lumbar spinal stenosis. *J Spinal Disord Tech*. 2014;27(6):336–341. doi:10.1097/BSD.0b013e31825f7203
148. Sobottke R, Röllinghoff M, Siewe J, et al. Clinical outcomes and quality of life 1 year after open microsurgical decompression or implantation of an interspinous stand-alone spacer. *Minim Invasive Neurosurg*. 2010;53(04):179–183. doi:10.1055/s-0030-1263108
149. Block JE, Lavelle WF, Nunley PD. Toward a cure for lumbar spinal stenosis: the potential of interspinous process decompression. *Medical Hypotheses*. 2019;132:109357. doi:10.1016/j.mehy.2019.109357
150. Meyer B, Baranto A, Schils F, et al. Percutaneous interspinous spacer vs decompression in patients with neurogenic claudication: an alternative in selected patients? *NEUROSURGERY*. 2018;82(5):621–629. doi:10.1093/neuros/nyx326
151. Moojen WA, Arts MP, Jacobs WCH, et al. IPD without bony decompression versus conventional surgical decompression for lumbar spinal stenosis: 2-year results of a double-blind randomized controlled trial. *Eur Spine J*. 2015;24(10):2295–2305. doi:10.1007/s00586-014-3748-2
152. Smith ZA. Interspinous process device versus standard conventional surgical decompression for lumbar spinal stenosis results in increased reoperation rates and costs without improving patient outcomes. *Evid Based Med*. 2014;19(4):136. doi:10.1136/eb-2013-101689
153. Tapp SJ, Martin BI, Tosteson TD, et al. Understanding the value of minimally invasive procedures for the treatment of lumbar spinal stenosis: the case of interspinous spacer devices. *Spine J*. 2018;18(4):584–592. doi:10.1016/j.spinee.2017.08.246
154. Vinas-Rios JM, Arabmotlagh M, Rahim T, Schmidt S, Sellei RM, Rauschmann M, et al. The importance of interspinous spacers in the treatment of lumbar spinal stenosis. *Orthopade*. 2019;48(10):831–836. doi:10.1007/s00132-019-03772-z
155. Croe R. It's the effect size stupid. What effect size is and why it is important. *British Educational Research Association*. 2002
156. Gum JL, Glassman SD, Carreon LY. Clinically important deterioration in patients undergoing lumbar spine surgery: a choice of evaluation methods using the Oswestry disability index, 36-item short form health survey, and pain scales: clinical article. *J Neurosurg Spine*. 2013;19(5):564–568. doi:10.3171/2013.8.SPINE12804
157. Staffa SJ, Zurakowski D. Statistical power and sample size calculations: a primer for pediatric surgeons. *Journal of Pediatric Surgery*. 2020;55(7):1173–1179. doi:10.1016/j.jpedsurg.2019.05.007
158. Garcia-Canadilla P, Sanchez-Martinez S, Crispi F, Bijnens B, et al. Machine learning in fetal cardiology: what to expect. *Fetal Diagn Ther*. 2020;47(5):363–372. doi:10.1159/000505021
159. Martínez CR, Lewandrowski K-U, Rugeles Ortíz JG, Alonso Cuéllar GO, Ramírez León JF, et al. Transforaminal endoscopic discectomy combined with an interspinous process distraction system for spinal stenosis. *Int J Spine Surg*. 2020;14(s3):S4–S12. doi:10.14444/7121
160. Qin R, Liu B, Hao J, et al. Percutaneous endoscopic lumbar discectomy versus posterior open lumbar microdiscectomy for the treatment of symptomatic lumbar disc herniation: a systemic

review and meta-analysis. *World Neurosurg.* 2018;120:352–362. doi:10.1016/j.wneu.2018.08.236

161. Lee C-H, Choi M, Ryu DS, et al. Efficacy and safety of full-endoscopic decompression via interlaminar approach for central or lateral recess spinal stenosis of the lumbar spine. *Spine.* 2018;43(24):1756–1764. doi:10.1097/BRS.0000000000002708

162. Phan K, Xu J, Schultz K, et al. Full-endoscopic versus micro-endoscopic and open discectomy: a systematic review and meta-analysis of outcomes and complications. *Clin Neurol Neurosurg.* 2017;154:1–12. doi:10.1016/j.clineuro.2017.01.003

163. Ma X-L, Zhao X-W, Ma J-X, Li F, Wang Y, Lu B, et al. Effectiveness of surgery versus conservative treatment for lumbar spinal stenosis: a system review and meta-analysis of randomized controlled trials. *Int J Surg.* 2017;44:329–338. doi:10.1016/j.ijssu.2017.07.032

164. Ruan W, Feng F, Liu Z, Xie J, Cai L, Ping A, et al. Comparison of percutaneous endoscopic lumbar discectomy versus open lumbar microdiscectomy for lumbar disc herniation: a meta-analysis. *Int J Surg.* 2016;31:86–92. doi:10.1016/j.ijssu.2016.05.061

165. Li X-C, Zhong C-F, Deng G-B, Liang R-W, Huang C-M, et al. Full-endoscopic procedures versus traditional discectomy surgery for discectomy: a systematic review and meta-analysis of current global clinical trials. *Pain Physician.* 2016;19(3):103–118. doi:10.36076/ppj/2019.19.103

166. He J, Xiao S, Wu Z, Yuan Z, et al. Microendoscopic discectomy versus open discectomy for lumbar disc herniation: a meta-analysis. *Eur Spine J.* 2016;25(5):1373–1381. doi:10.1007/s00586-016-4523-3

167. Goldstein CL, Macwan K, Sundararajan K, Rampersaud YR, et al. Perioperative outcomes and adverse events of minimally invasive versus open posterior lumbar fusion: meta-analysis and systematic review. *J Neurosurg Spine.* 2016;24(3):416–427. doi:10.3171/2015.2.SPINE14973

168. Concato J, Shah N, Horwitz RI. Randomized, controlled trials, observational studies, and the hierarchy of research designs. *N Engl J Med.* 2000;342(25):1887–1892. doi:10.1056/NEJM200006223422507

169. Benson K, Hartz AJ. A comparison of observational studies and randomized, controlled trials. *N Engl J Med.* 2000;342(25):1878–1886. doi:10.1056/NEJM200006223422506

**Funding:** The author(s) received no financial support for the research, authorship, and/or publication of this article.

**Declaration of Conflicting Interests:** This manuscript is not meant for or intended to endorse any products or push any other agenda other than the associated clinical outcomes with endoscopic spine surgery. The motive for compiling this clinically relevant information is by no means created and/or correlated to directly enrich anyone due to its publication. This publication was intended to substantiate contemporary endoscopic spinal surgery concepts to facilitate technology advancements.

**Disclaimer:** The views expressed in this editorial represent those of the authors and no other entity or organization. The authors are accountable for all aspects of the work in ensuring that questions related to the accuracy or integrity of any part of the work are appropriately investigated and resolved.

**Corresponding Author:** Kai-Uwe Lewandrowski, Center for Advanced Spine Care of Southern Arizona and Surgical Institute of Tucson, Tucson, AZ, USA; business@tucsonspine.com

This manuscript is generously published free of charge by ISASS, the International Society for the Advancement of Spine Surgery. Copyright © 2021 ISASS. To see more or order reprints or permissions, see <http://ijssurgery.com>.